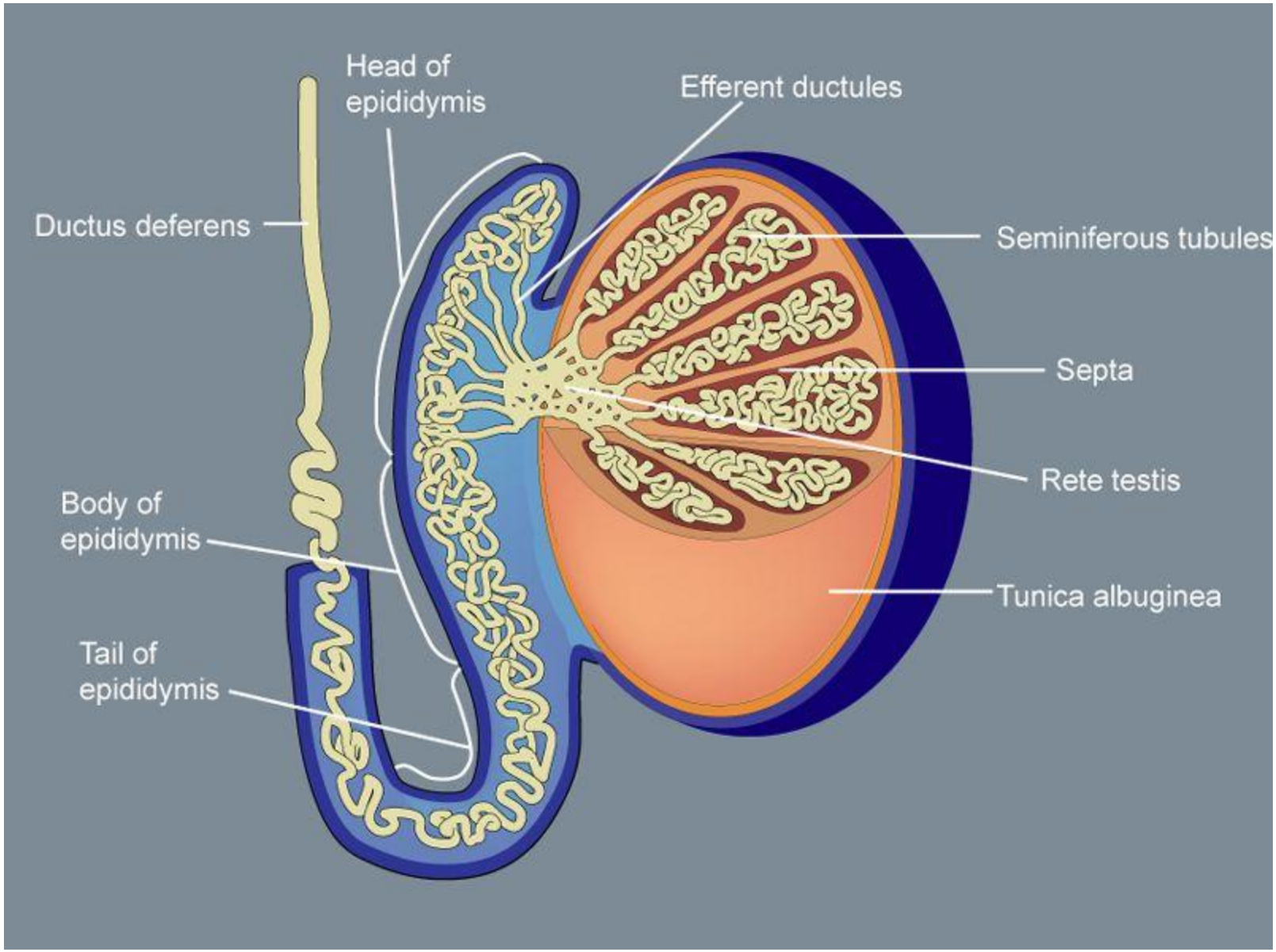
Head of epididymis
Efferent ductules
Ductus deferens
Seminiferous tubules
Septa
Rete testis
Body of epididymis
Tunica albuginea
Tail of epididymis

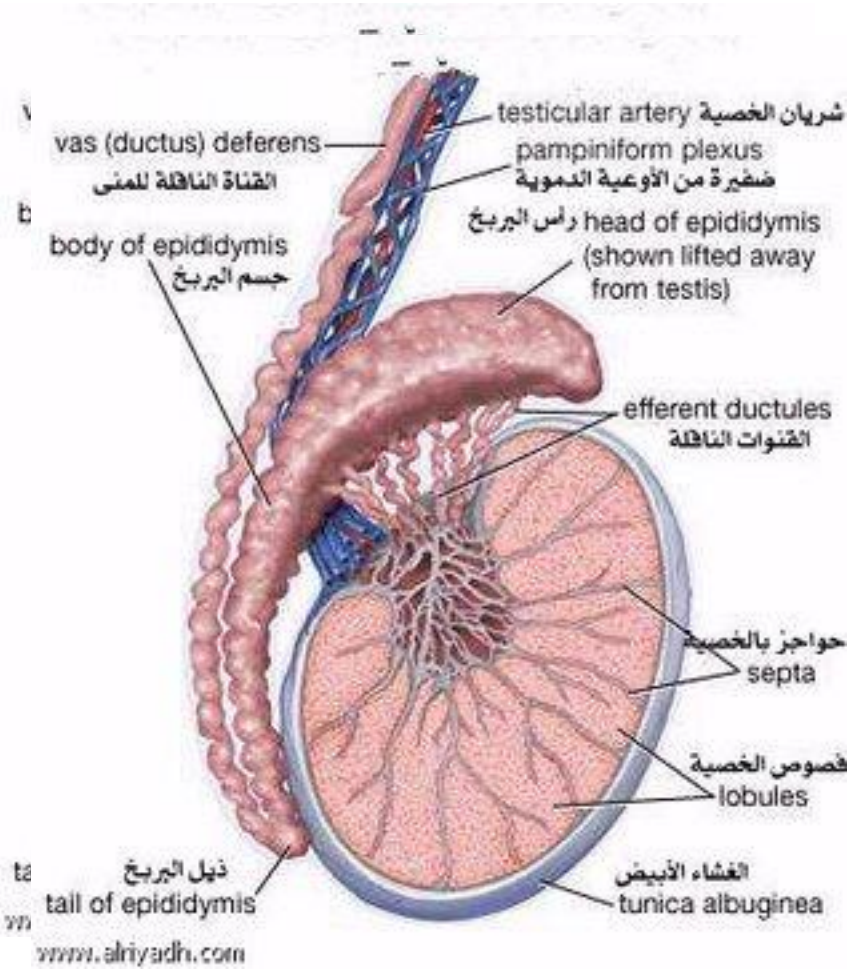
testicular artery شريان الخصية
vas (ductus) deferens
القناة الناقلة للمنى
pampiniform plexus
ضفيرة من الأوعية الدموية
head of epididymis رأس البربخ
(shown lifted away
from testis)
body of epididymis
جسم البربخ
efferent ductules
القنوات الناقلة
حواجز بالخصية
septa
فصوص الخصية
lobules
ذيل البربخ
tail of epididymis
الغشاء الأبيض
tunica albuginea
www.alriyadh.com

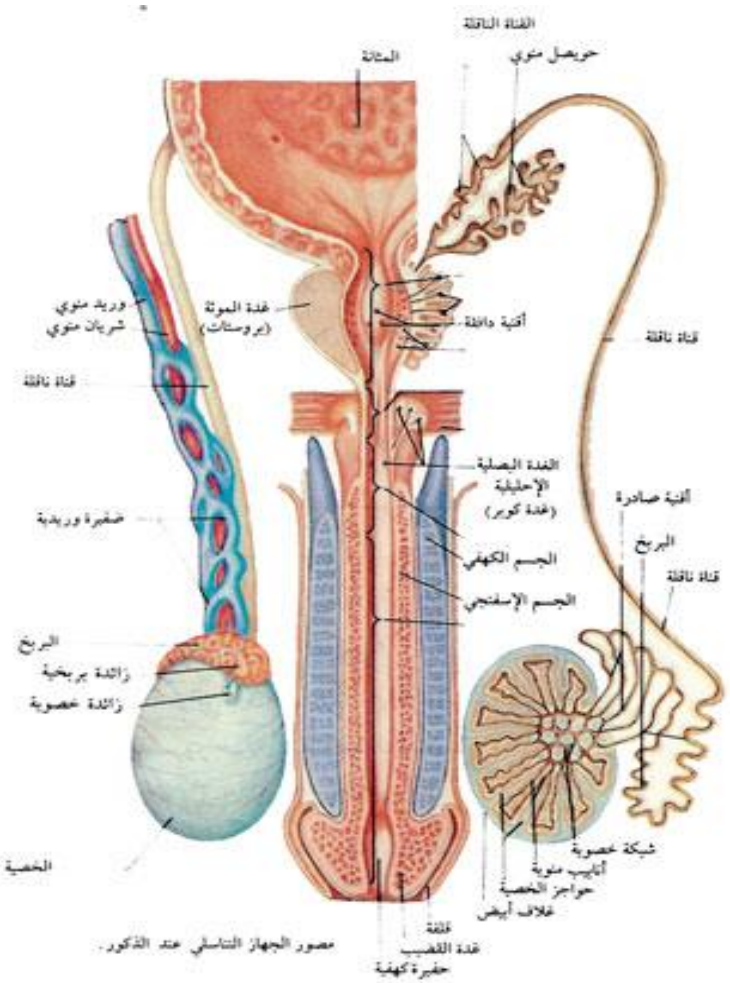
القناة الناقلة
المثانة
حويصل منوي
وريد منوي
شريان منوي
غدة المبولة
(بروستات)
أقنية دافقة
قناة ناقلة
قناة ناقلة
الغدة البصلية
الإحليلية
(غدة كوبر)
أقنية صادرة
ضفيرة وريدية
البربخ
الجسم الكهفي
قناة ناقلة
الجسم الإسفنجي
البربخ
زائدة بربخية
زائدة خصوية
شبكة خصوية
أنابيب منوية
حواجز الخصية
غلاف أبيض
الخصية
مصور الجهاز التناسلي عند الذكور.
قلفة
غدة القضيب
حفيرة كهفية

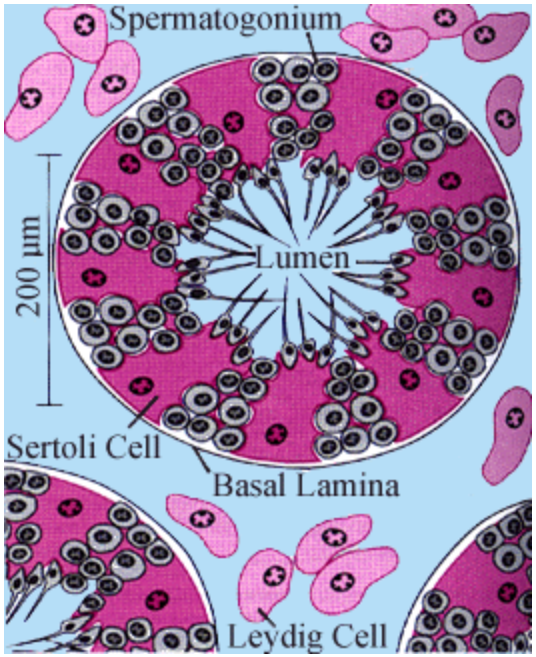
Spermatogonium
200 µm
Lumen
Sertoli Cell
Basal Lamina
Leydig Cell

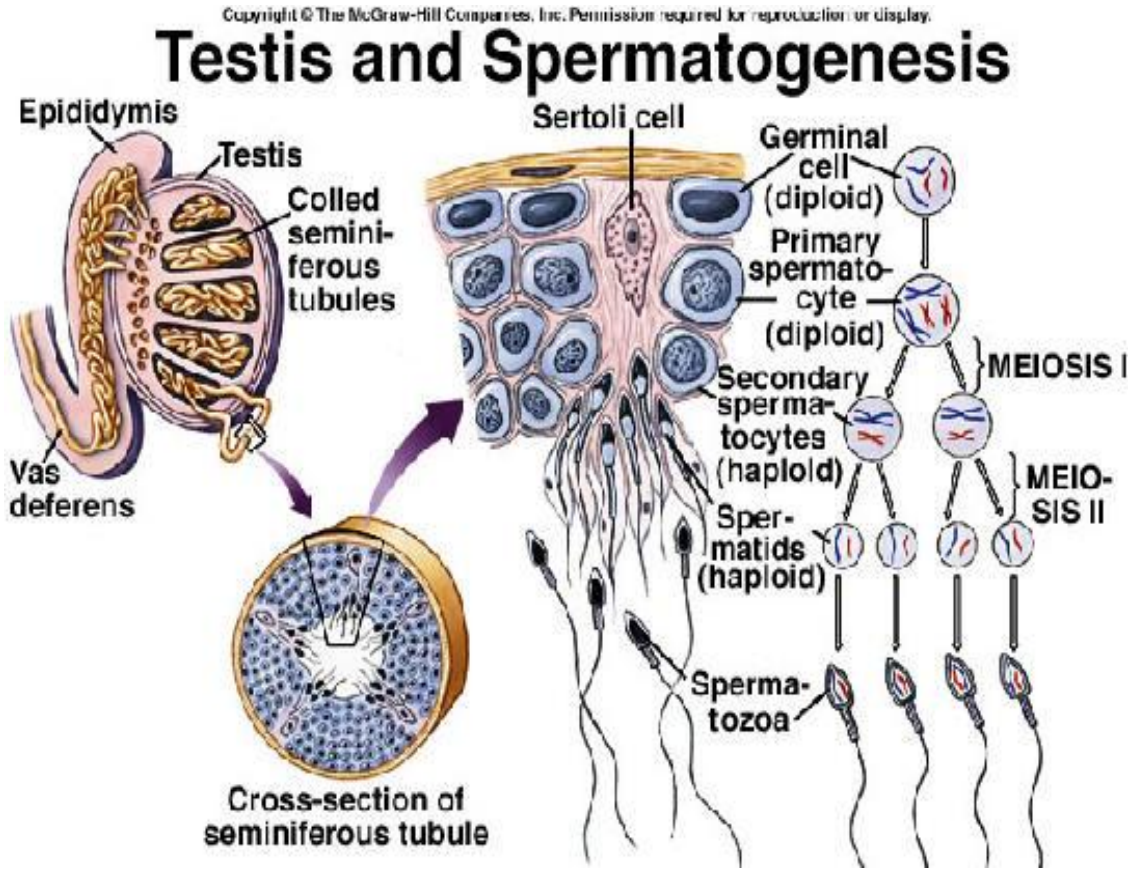
Copyright © The McGraw-Hill Companies, Inc. Permission required for reproduction or display.
Testis and Spermatogenesis
Epididymis
Testis
Coiled seminiferous tubules
Vas deferens
Sertoli cell
Germinal cell (diploid)
Primary spermatocyte (diploid)
MEIOSIS I
Secondary spermatocytes (haploid)
MEIOSIS II
Spermatids (haploid)
Spermatozoa
Cross-section of seminiferous tubule

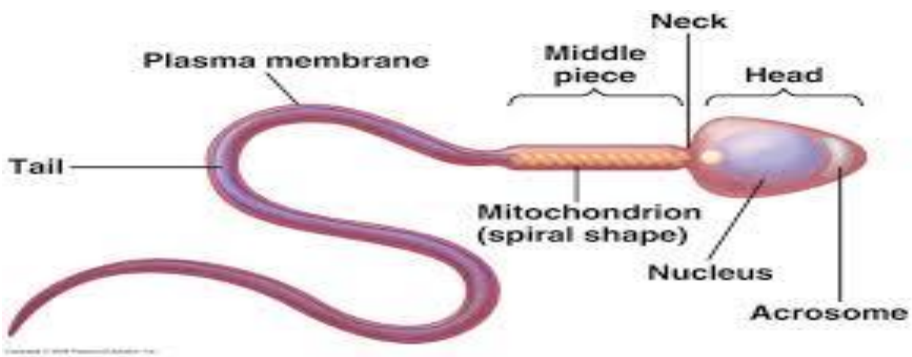
Neck
Plasma membrane
Middle piece
Head
Tail
Mitochondrion (spiral shape)
Nucleus
Acrosome

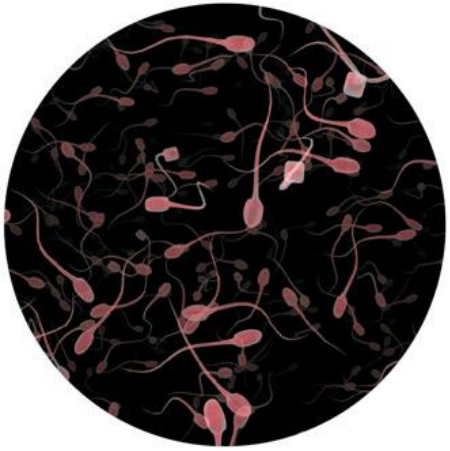

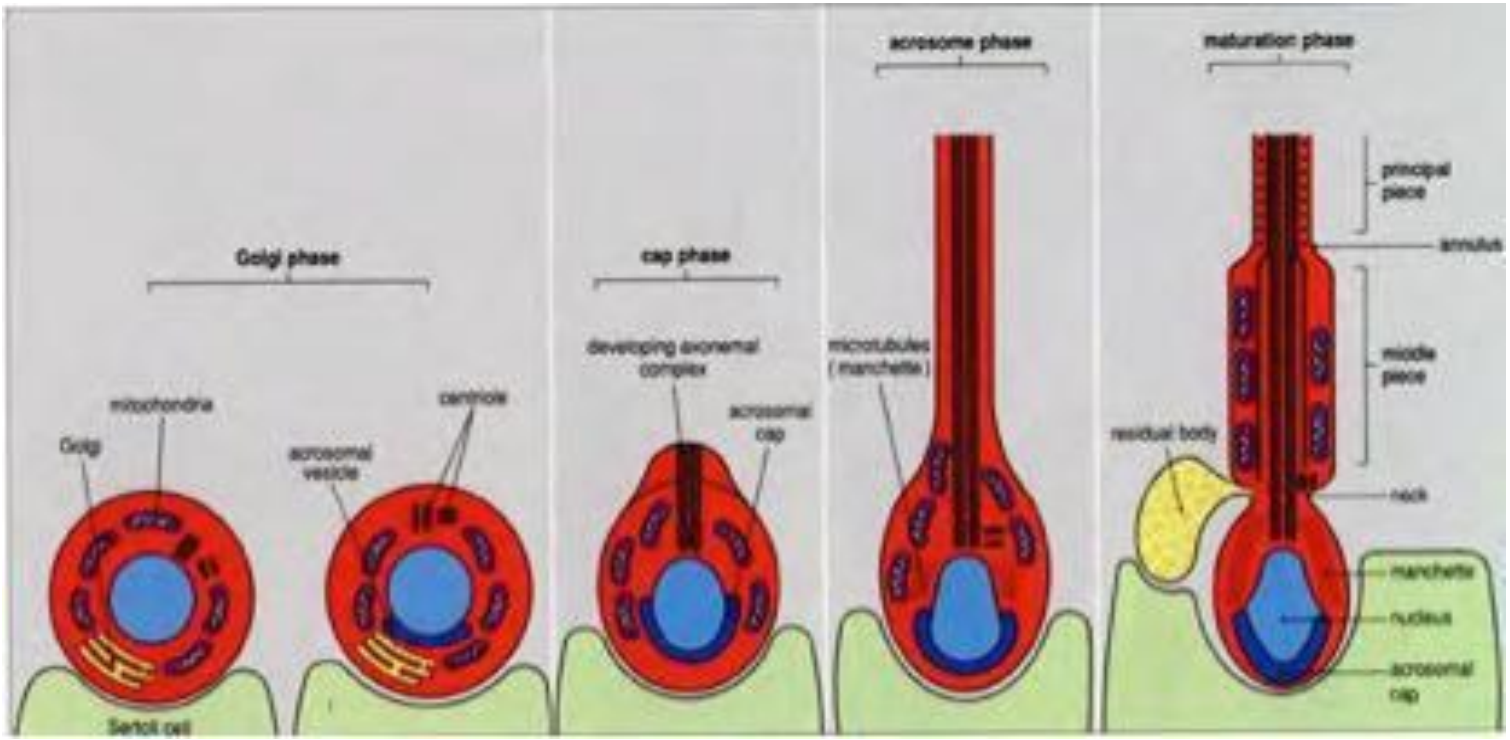
Golgi phase
cap phase
acrosome phase
maturation phase
mitochondria
Golgi
acrosomal vesicle
centriole
developing axonemal complex
acrosomal cap
microtubules (manchette)
principal piece
annulus
middle piece
residual body
neck
manchette
nucleus
acrosomal cap
Sertoli cell

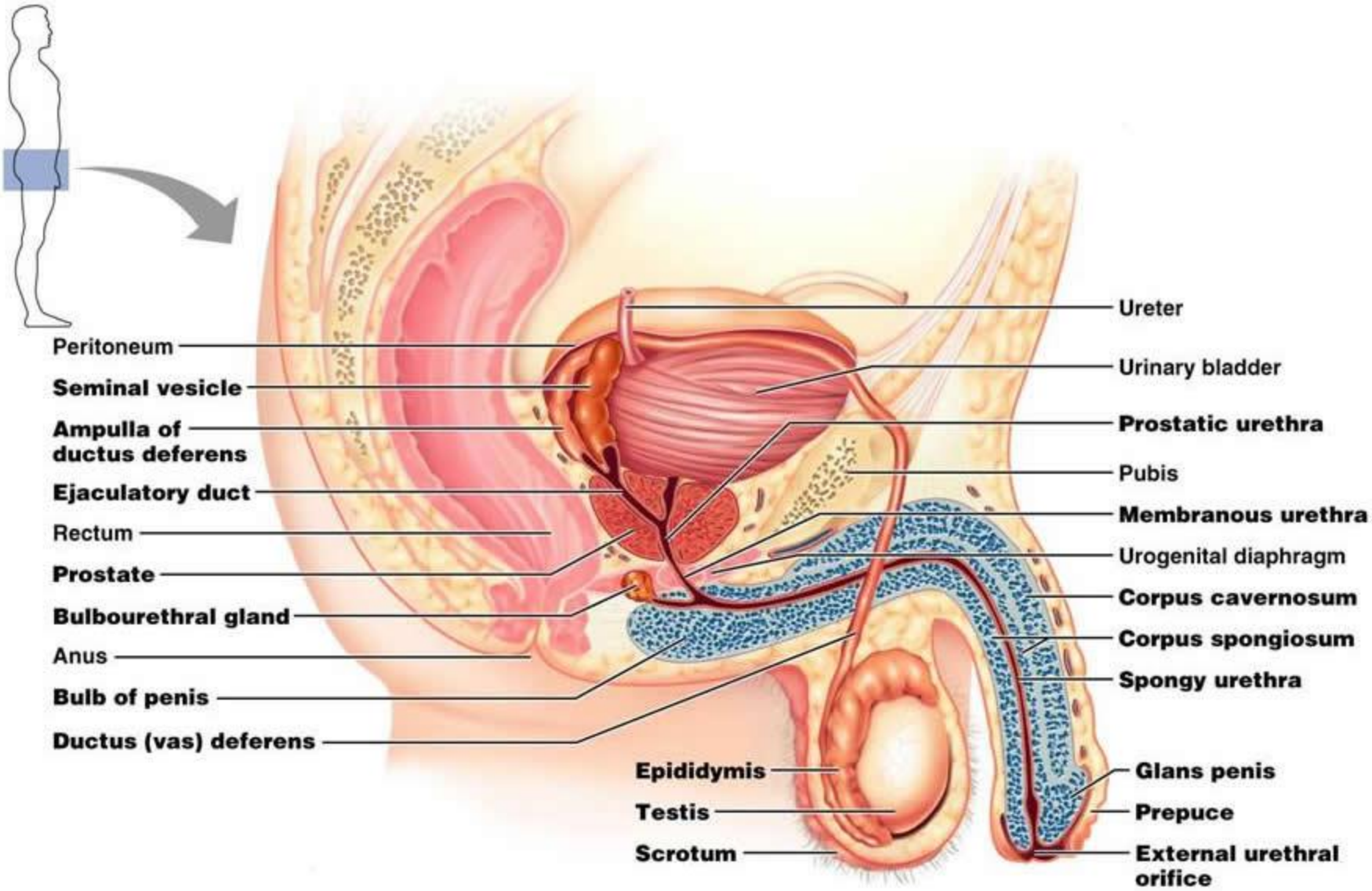
Peritoneum
Seminal vesicle
Ampulla of ductus deferens
Ejaculatory duct
Rectum
Prostate
Bulbourethral gland
Anus
Bulb of penis
Ductus (vas) deferens
Epididymis
Testis
Scrotum
Ureter
Urinary bladder
Prostatic urethra
Pubis
Membranous urethra
Urogenital diaphragm
Corpus cavernosum
Corpus spongiosum
Spongy urethra
Glans penis
Prepuce
External urethral orifice

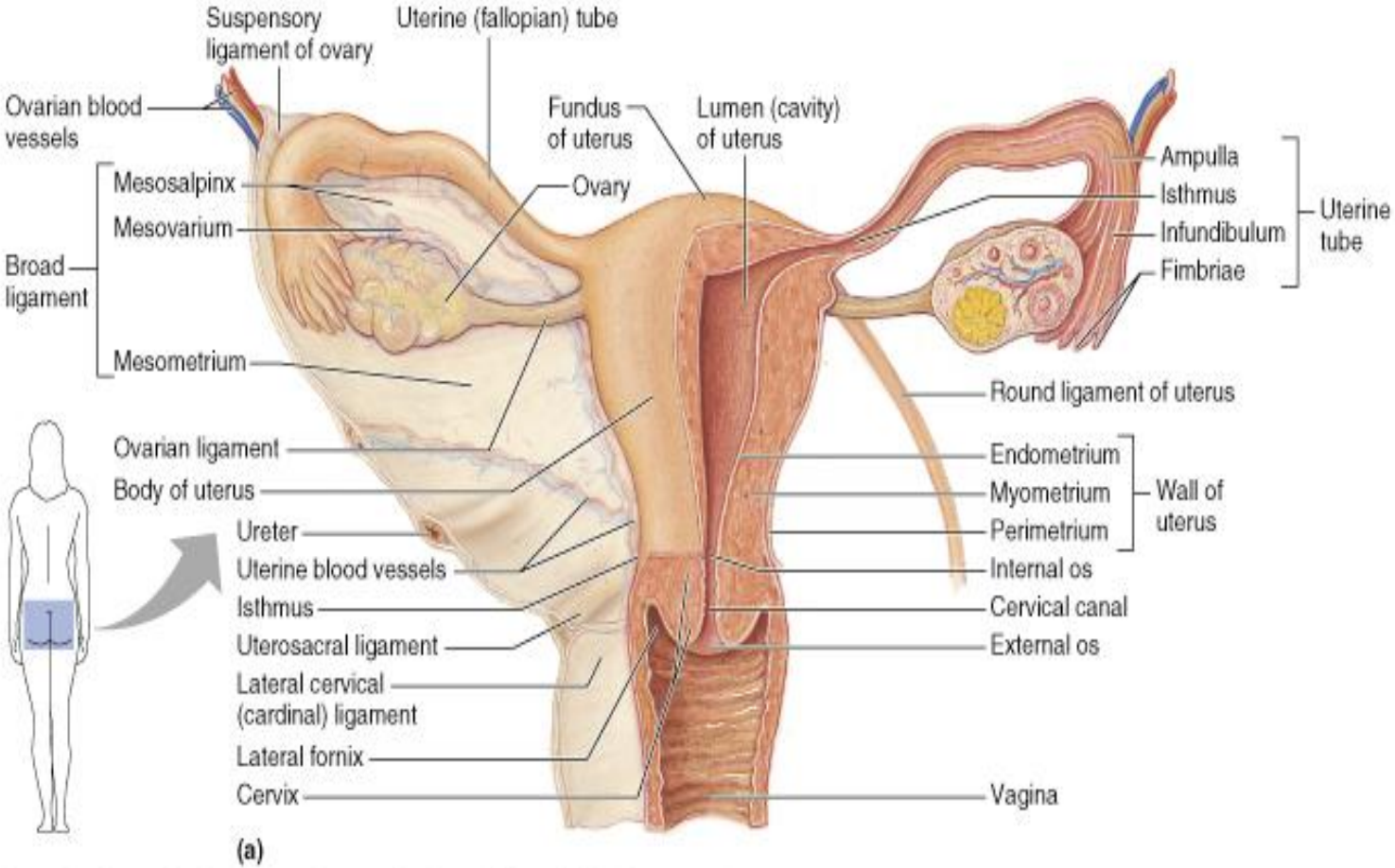

Copyright © 2001 Benjamin Cummings, an imprint of Addison Wesley Longman, Inc.

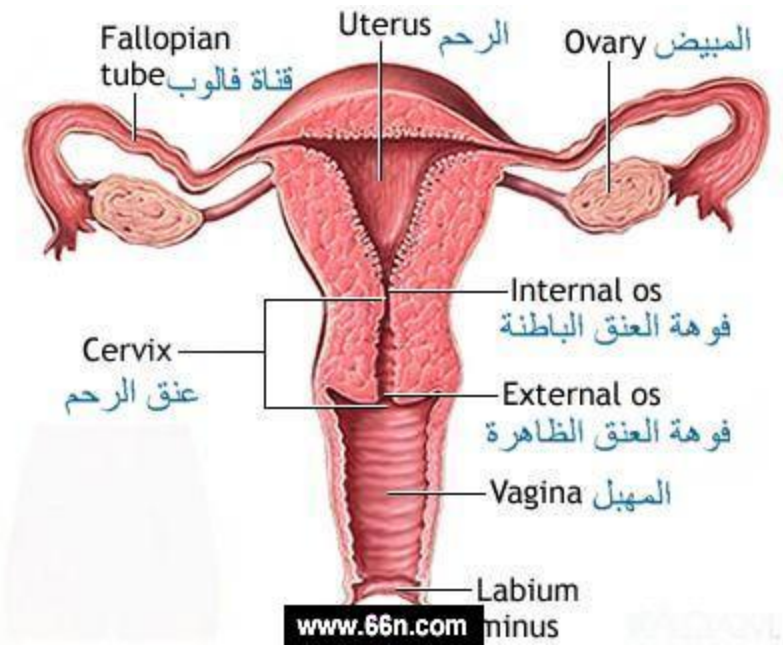
Fallopian tube قناة فالوب
Uterus الرحم
Ovary المبيض
Internal os
فوهة العنق الباطنة
Cervix
عنق الرحم
External os
فوهة العنق الظاهرة
Vagina المهبل
Labium minus
www.66n.com

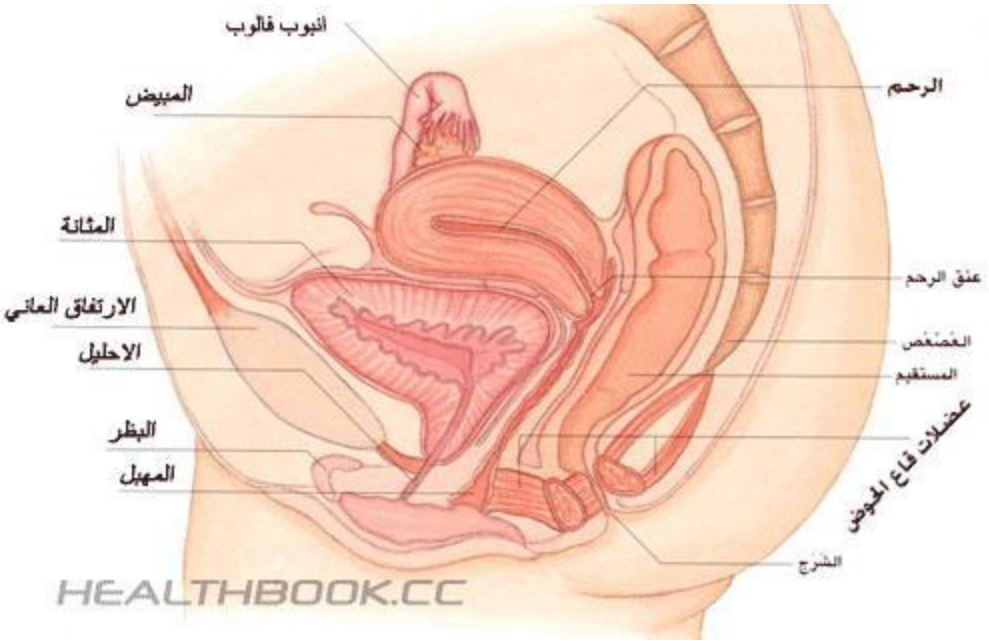
انبوب فالوب
المبيض
الرحم
المثانة
عنق الرحم
الارتفاق العاني
العُصْعُص
الاحليل
المستقيم
البظر
عضلات قاع الحوض
المهبل
الشرج
HEALTHBOOK.CC

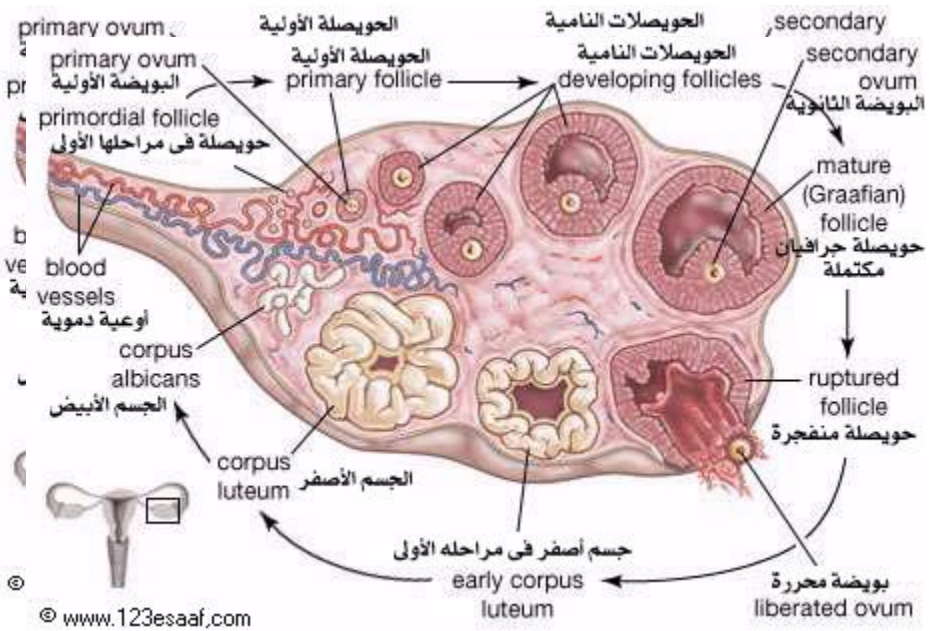
primary ovum
الحويصلة الأولية
الحويصلات النامية
secondary
primary ovum
البويضة الأولية
الحويصلة الأولية
primary follicle
الحويصلات النامية
developing follicles
secondary
ovum
البويضة الثانوية
primordial follicle
حويصلة فى مراحلها الأولى
mature
(Graafian)
follicle
حويصلة جرافيان
مكتملة
blood
vessels
أوعية دموية
corpus
albicans
الجسم الأبيض
ruptured
follicle
حويصلة منفجرة
corpus
luteum
الجسم الأصفر
جسم أصفر فى مراحله الأولى
early corpus
luteum
بويضة محررة
liberated ovum
© www.123esaaf.com

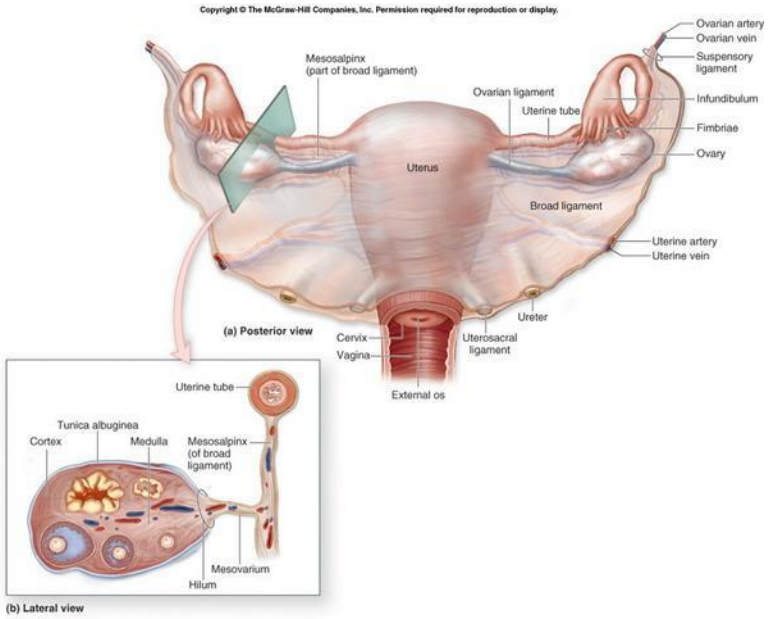
Copyright © The McGraw-Hill Companies, Inc. Permission required for reproduction or display.
Ovarian artery
Ovarian vein
Suspensory ligament
Mesosalpinx (part of broad ligament)
Ovarian ligament
Uterine tube
Infundibulum
Fimbriae
Ovary
Uterus
Broad ligament
Uterine artery
Uterine vein
Ureter
(a) Posterior view
Cervix
Vagina
Uterosacral ligament
External os
Uterine tube
Tunica albuginea
Cortex
Medulla
Mesosalpinx (of broad ligament)
Mesovarium
Hilum
(b) Lateral view

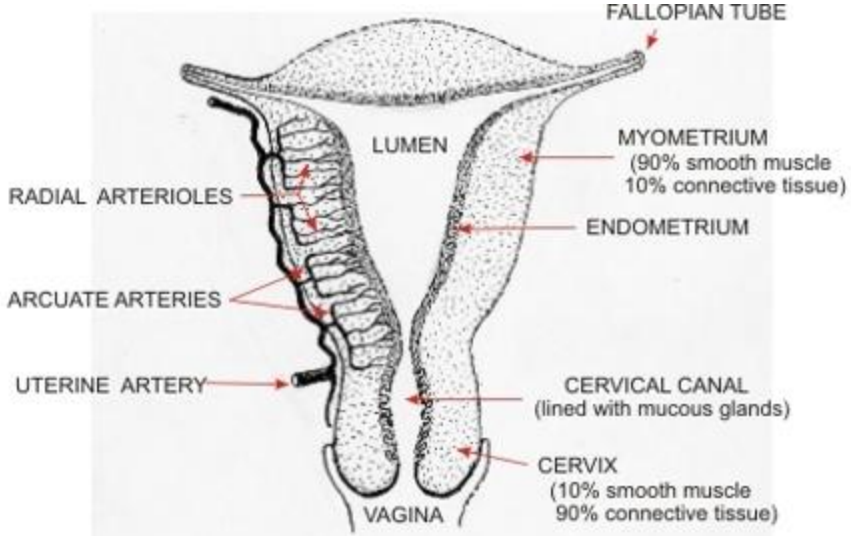
FALLOPIAN TUBE
LUMEN
MYOMETRIUM
(90% smooth muscle
10% connective tissue)
RADIAL ARTERIOLES
ENDOMETRIUM
ARCUATE ARTERIES
UTERINE ARTERY
CERVICAL CANAL
(lined with mucous glands)
CERVIX
(10% smooth muscle
90% connective tissue)
VAGINA

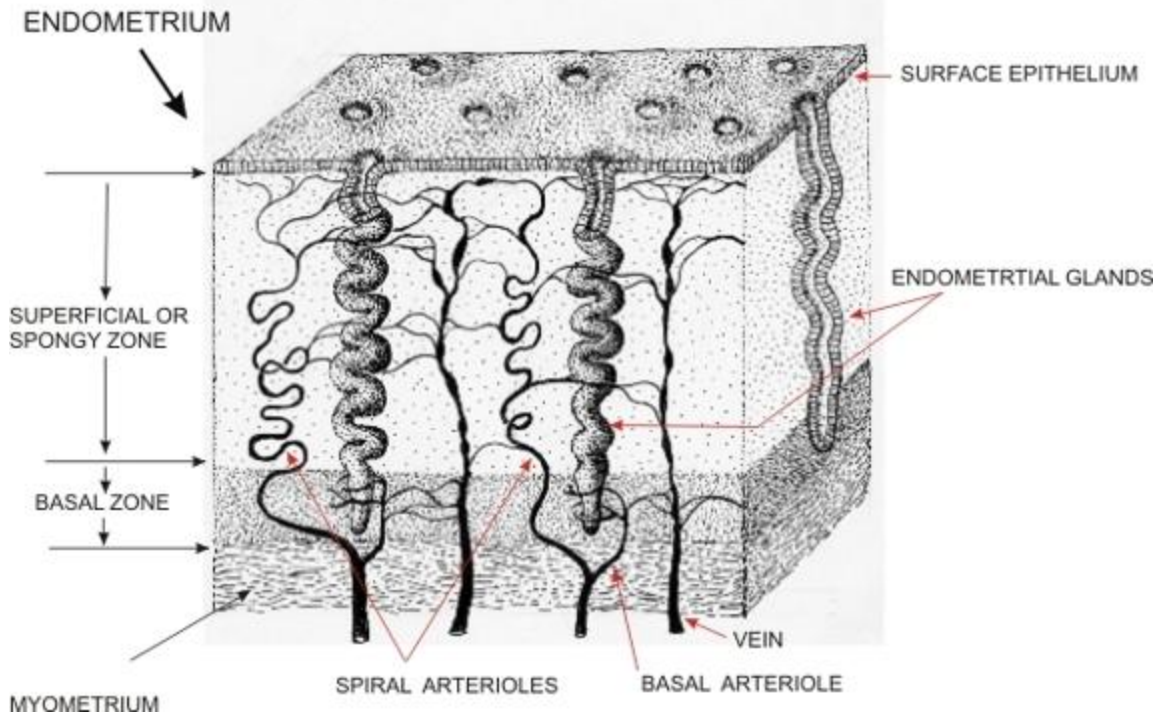
ENDOMETRIUM
SURFACE EPITHELIUM
ENDOMETRTIAL GLANDS
SUPERFICIAL OR
SPONGY ZONE
BASAL ZONE
VEIN
MYOMETRIUM
SPIRAL ARTERIOLES
BASAL ARTERIOLE

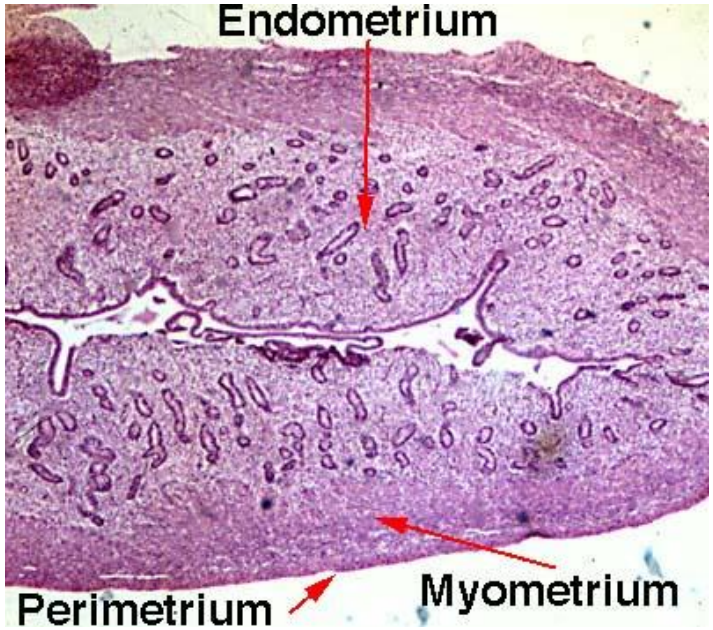
Endometrium
Perimetrium
Myometrium

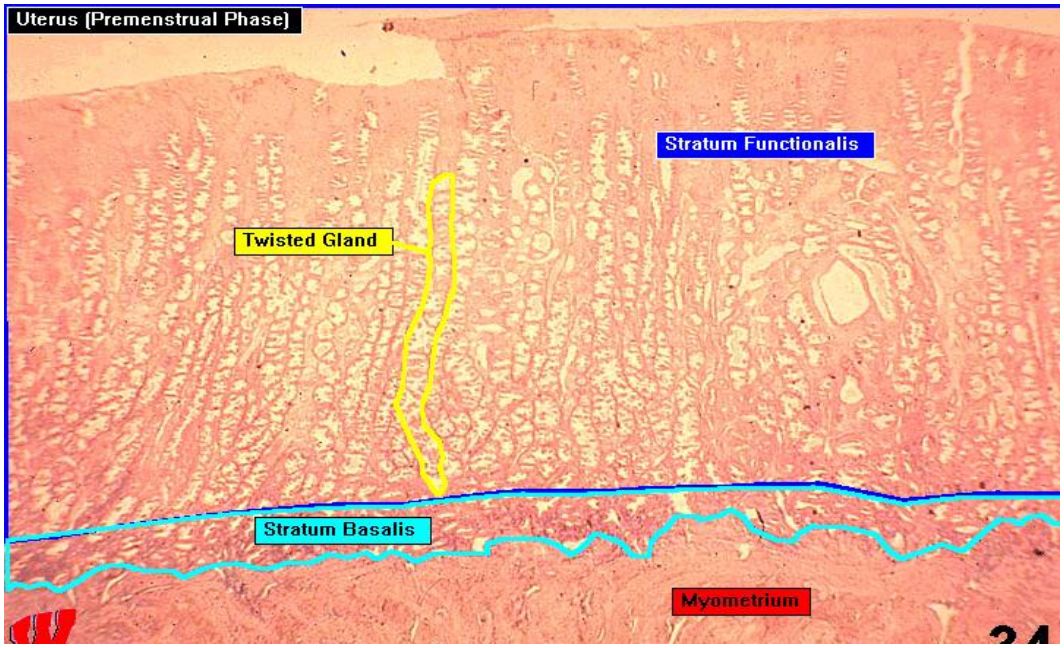
Uterus (Premenstrual Phase)
Stratum Functionalis
Twisted Gland
Stratum Basalis
Myometrium

Copyright © The McGraw-Hill Companies, Inc. Permission required for reproduction or display.

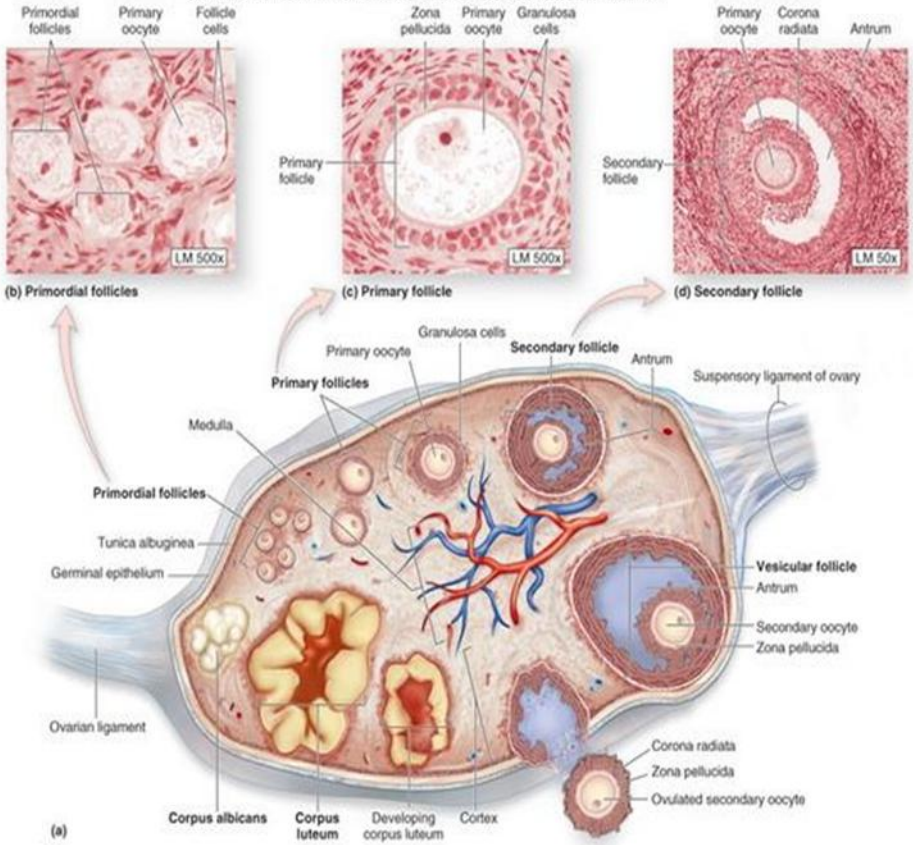

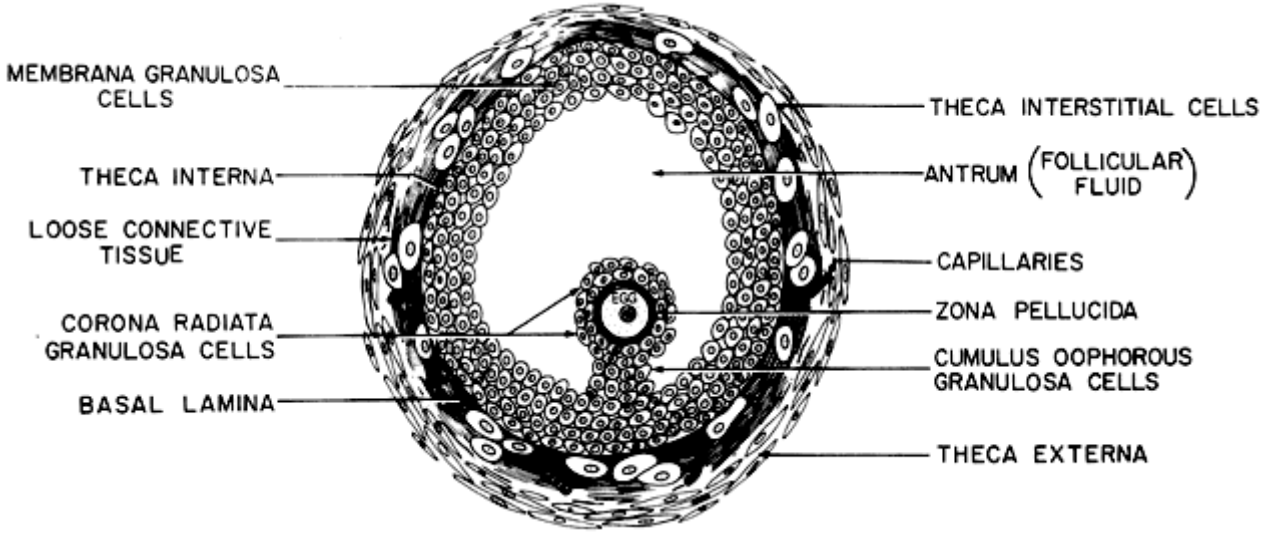

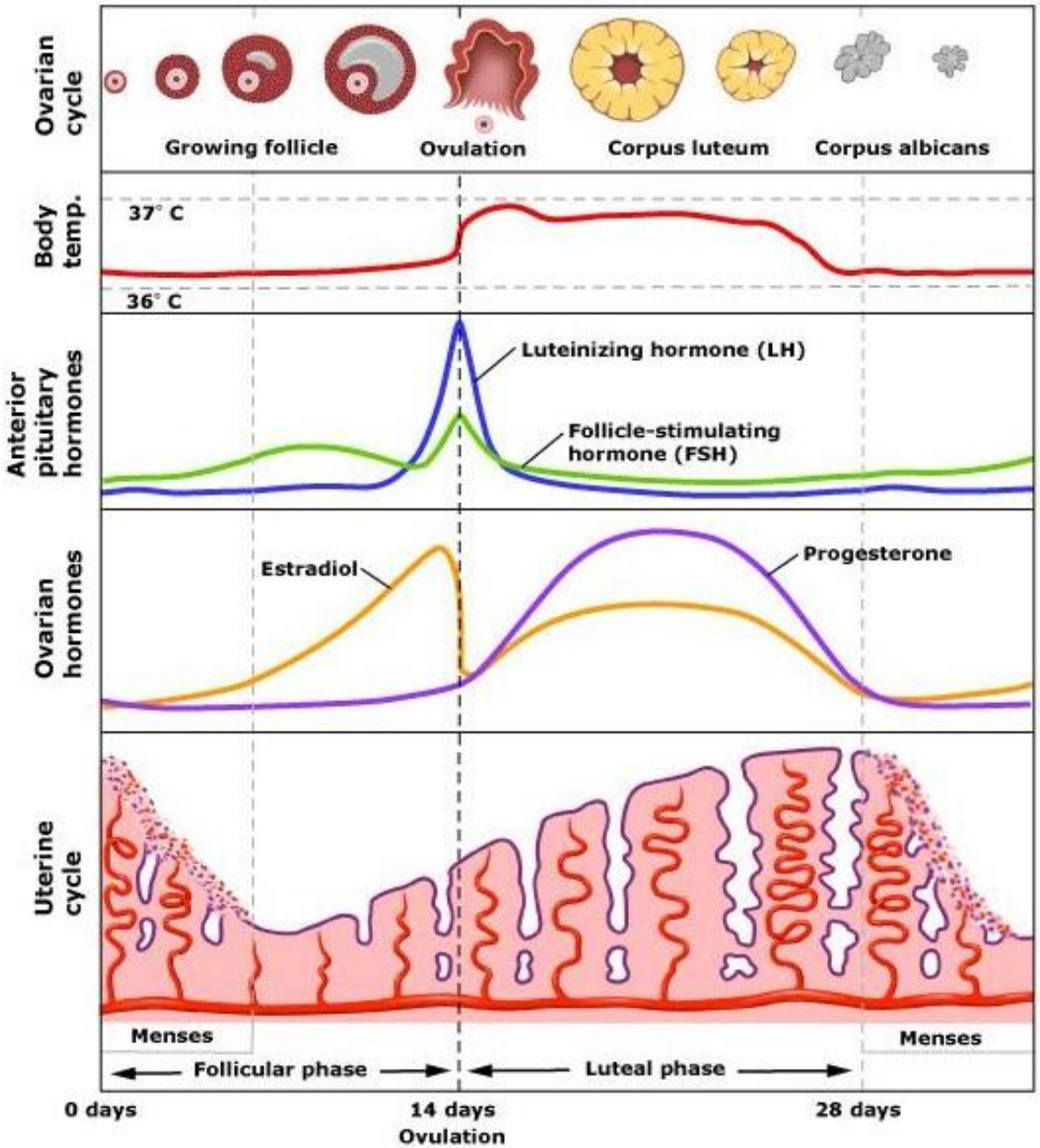
Ovarian cycle
Growing follicle
Ovulation
Corpus luteum
Corpus albicans
Body temp.
37° C
36° C
Anterior pituitary hormones
Luteinizing hormone (LH)
Follicle-stimulating hormone (FSH)
Ovarian hormones
Estradiol
Progesterone
Uterine cycle
Menses
Menses
Follicular phase
Luteal phase
0 days
14 days
Ovulation
28 days

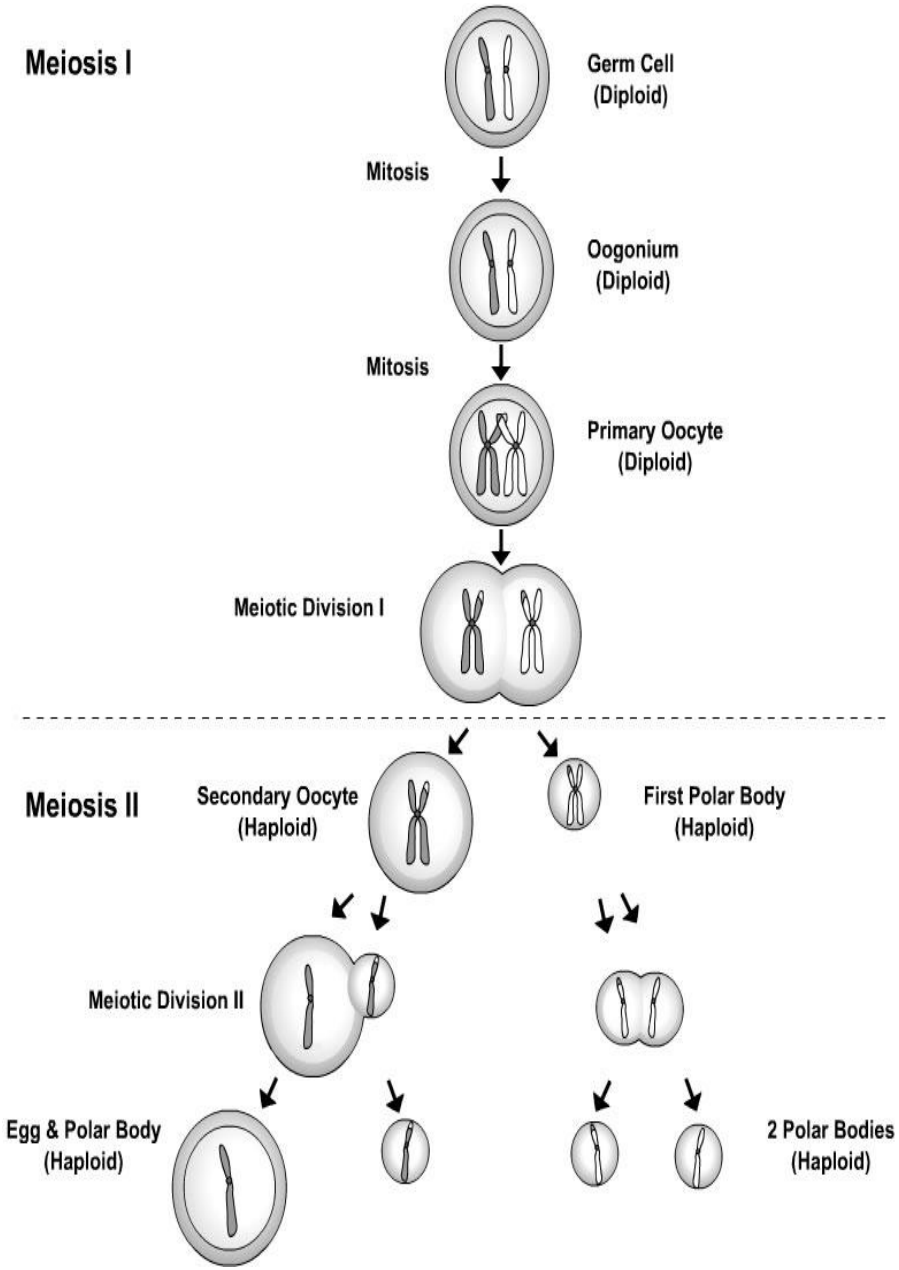

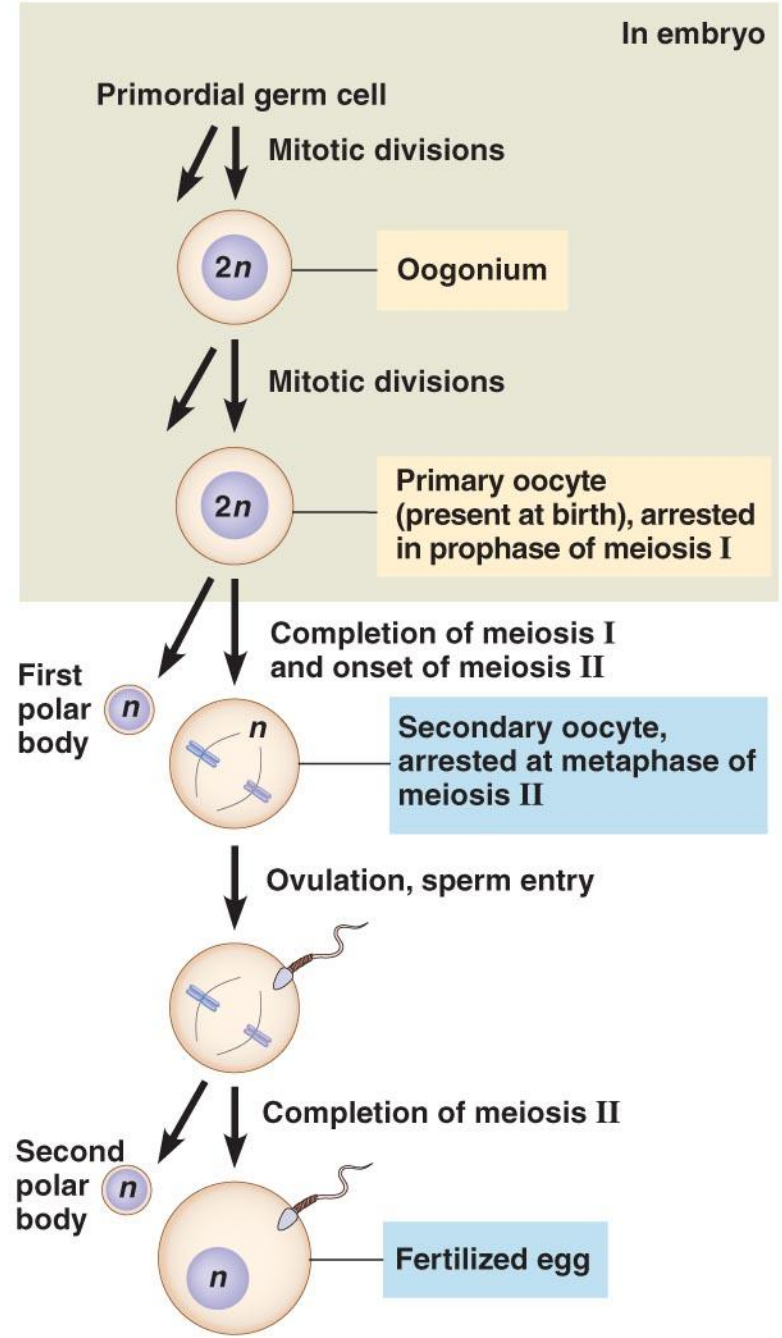

Copyright © 2008 Pearson Education, Inc., publishing as Pearson Benjamin Cummings.

Spermatogenesis

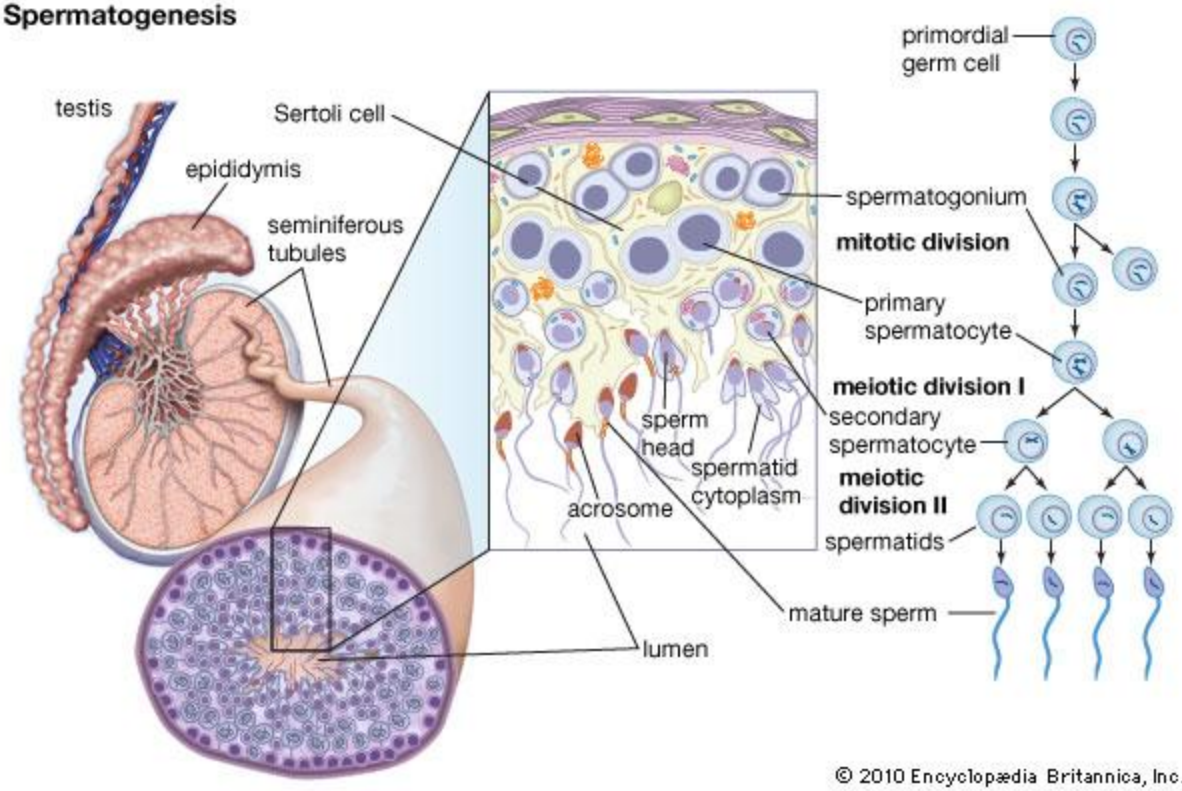

© 2010 Encyclopædia Britannica, Inc.

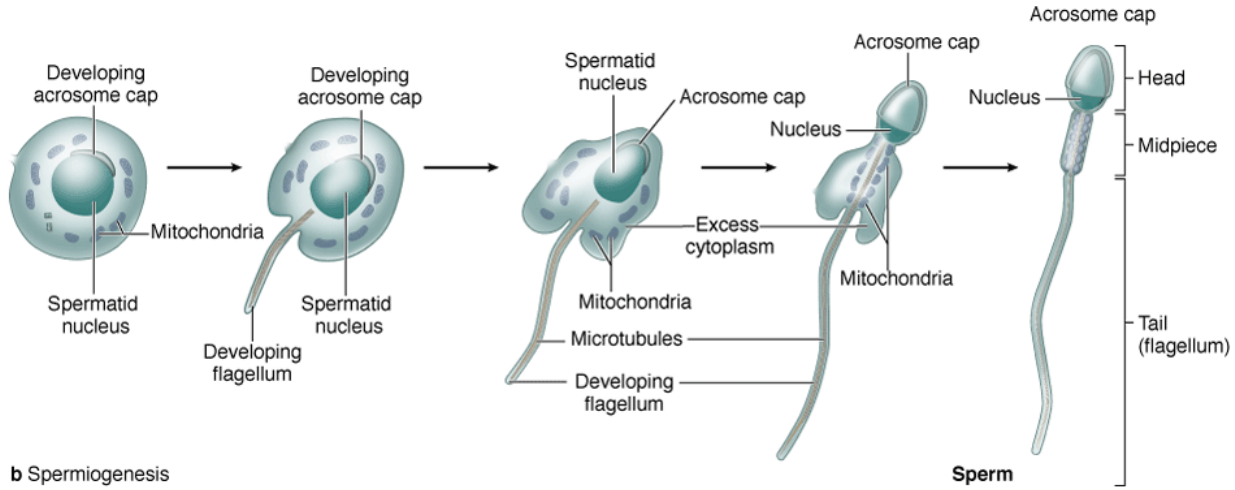

Source: Mescher AL: *Junqueira's Basic Histology: Text and Atlas, 12th Edition:* http://www.accessmedicine.com
Copyright © The McGraw-Hill Companies, Inc. All rights reserved.

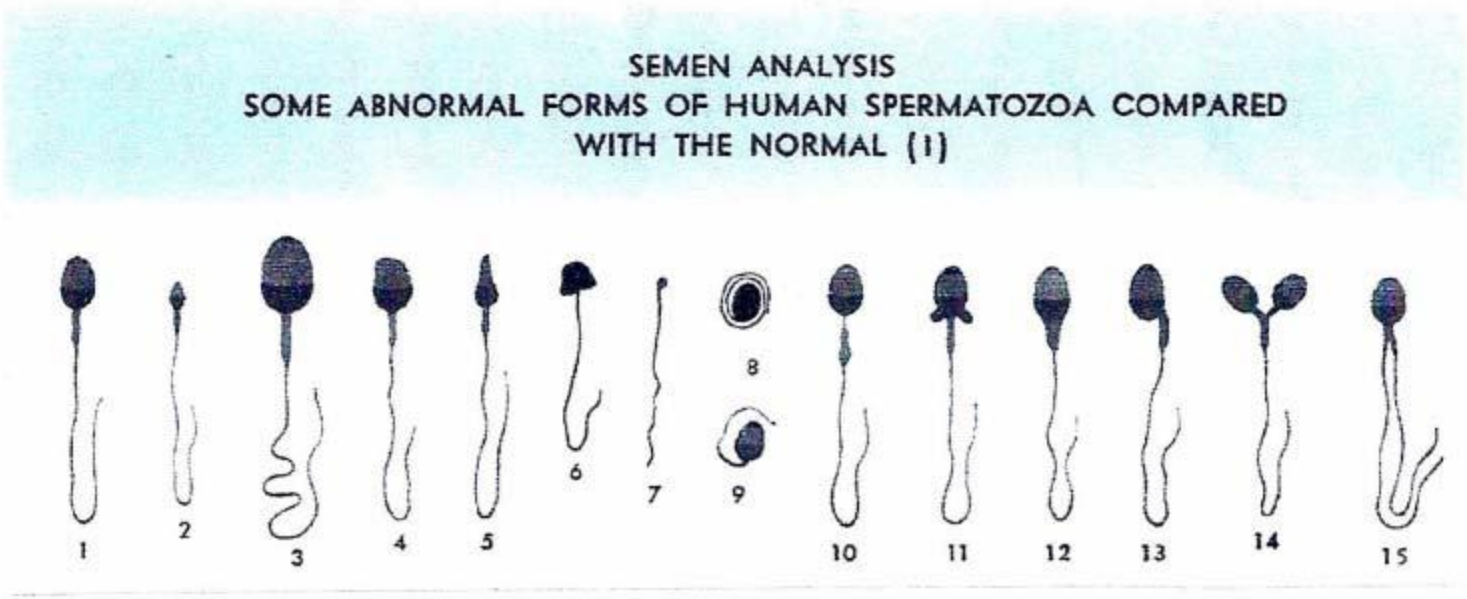

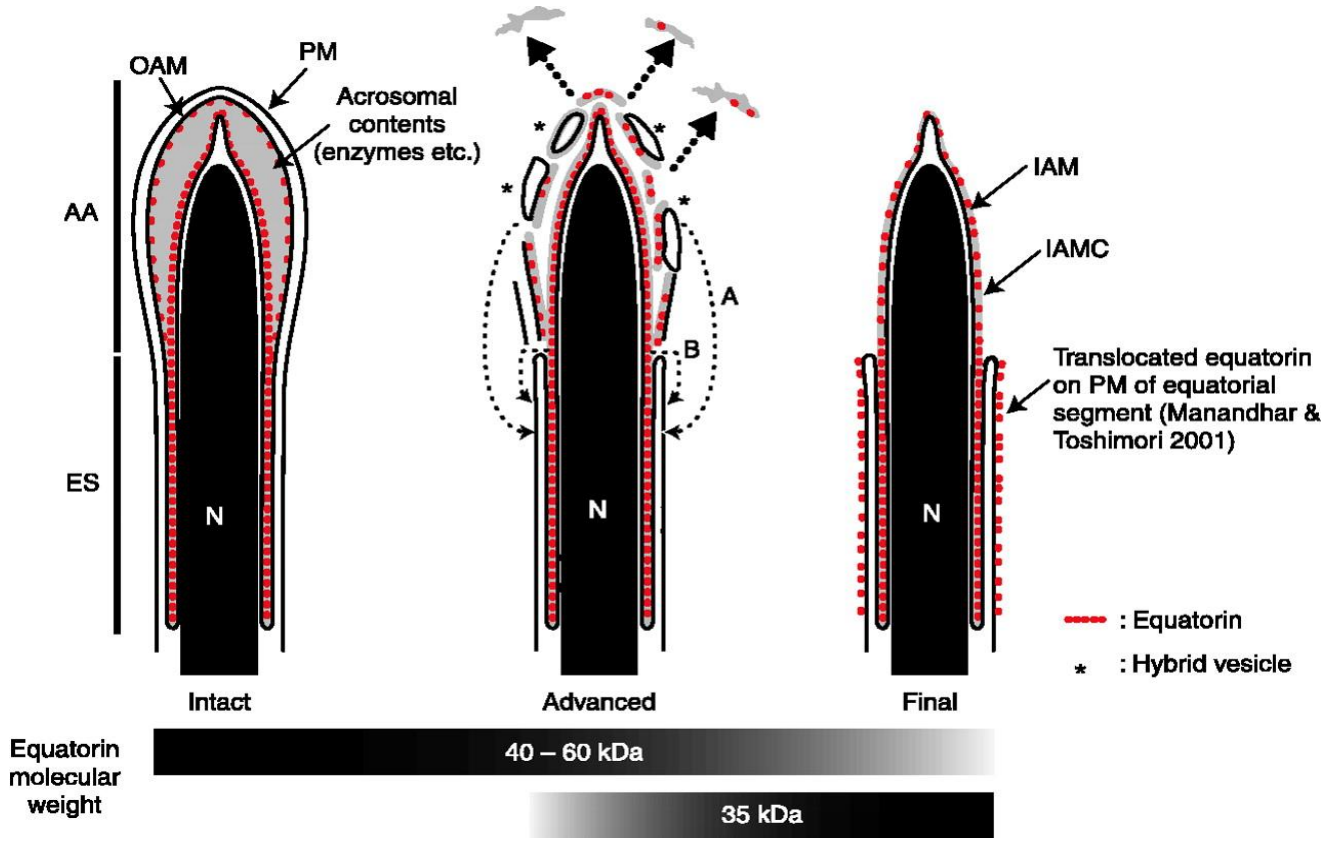
OAM
PM
Acrosomal contents (enzymes etc.)
AA
ES
N
Intact
A
B
Advanced
IAM
IAMC
Translocated equatorin on PM of equatorial segment (Manandhar & Toshimori 2001)
Final
: Equatorin
: Hybrid vesicle
Equatorin molecular weight
40 – 60 kDa
35 kDa

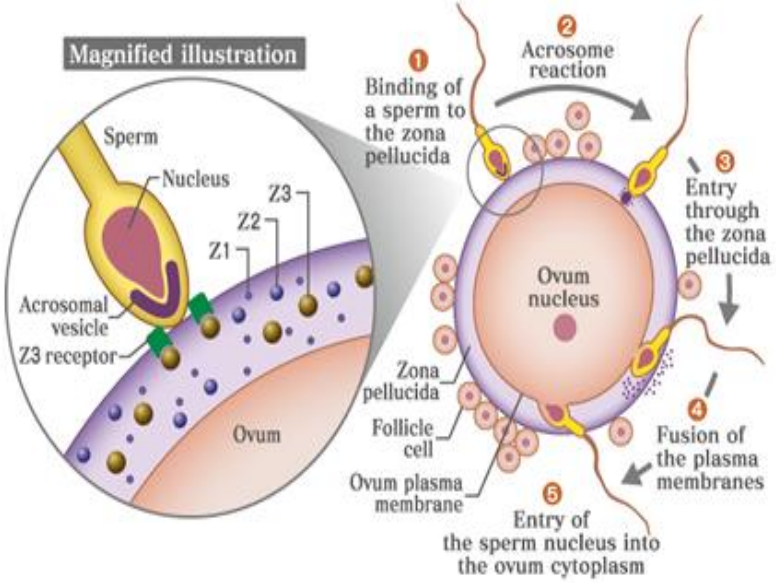
Magnified illustration
Sperm
Nucleus
Z3
Z2
Z1
Acrosomal vesicle
Z3 receptor
Ovum
1 Binding of a sperm to the zona pellucida
2 Acrosome reaction
3 Entry through the zona pellucida
Ovum nucleus
Zona pellucida
Follicle cell
Ovum plasma membrane
4 Fusion of the plasma membranes
5 Entry of the sperm nucleus into the ovum cytoplasm

ZOOM

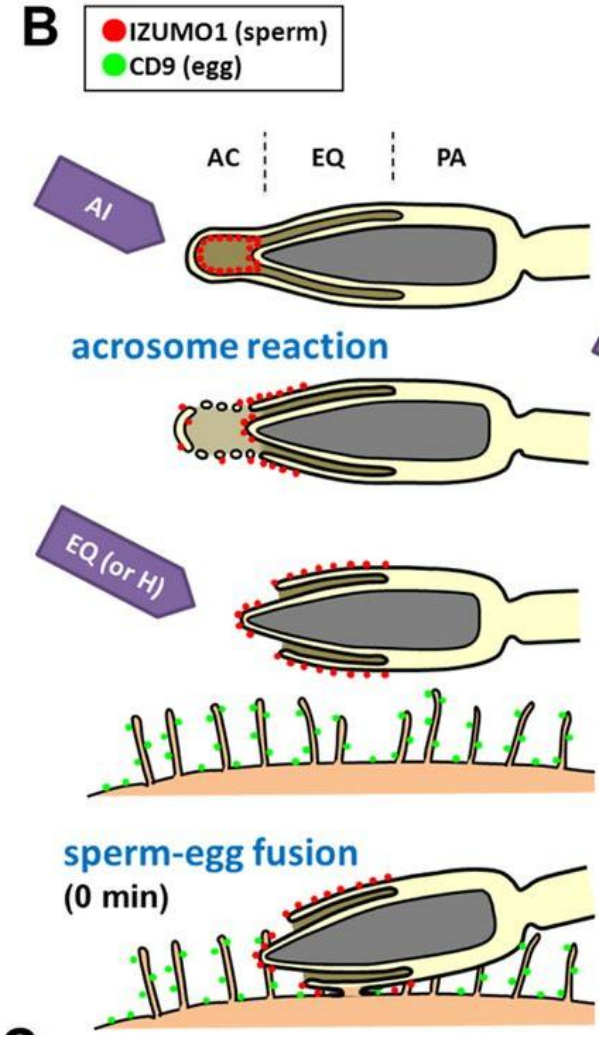
B
IZUMO1 (sperm)
CD9 (egg)
AC
EQ
PA
AI
acrosome reaction
EQ (or H)
sperm-egg fusion
(0 min)

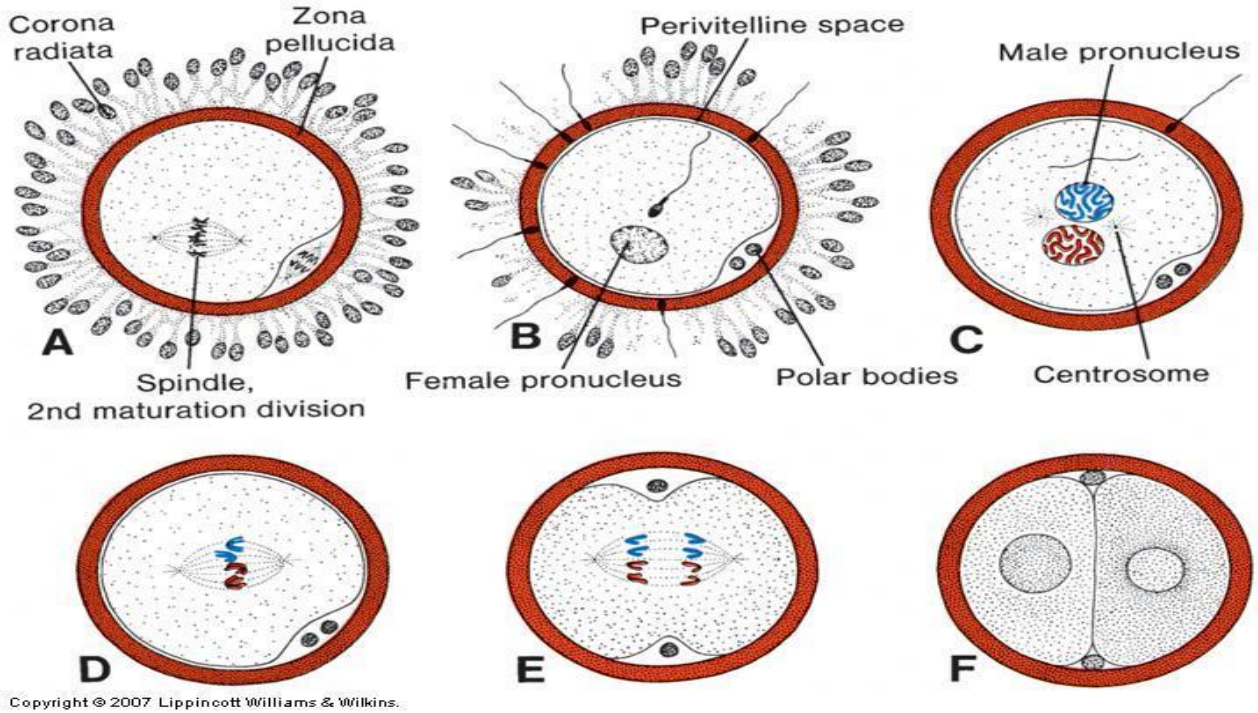

A - الخلية البيضية بعد الاباضة مباشرة ، يظهر مغازل الانقسام المنصف الثاني

B. النطفة مخترقة الخلية البيضية التي أكملت انقسامها المنصف الثاني ، انتظام صبغيات الخلية البيضية في النواةالحويصلية تعرف بالنواة البدئية الأنثوية ، التصاق رؤوس عدد من النطاف بالغشاء الشفيف

C- اقتراب النواة البدئية الذكرية من النواة البدئية الأنثوية ، ينفصل الذيل ويتنكس

E&D- الصبغيات تنتظم في المغزل ، وتنشق طولياً وتتحرك إلى القطب المقابل F- مرحلة الخليتين الأصل

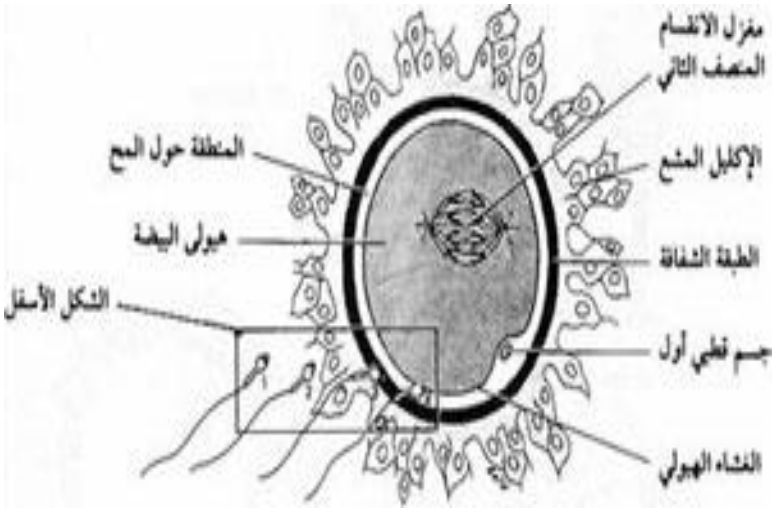
مغزل الانقسام
المنصف الثاني
المنطقة حول المح
الإكليل المشع
هيولى البيضة
الطبقة الشفافة
الشكل الأسفل
جسم قطبي أول
الغشاء الهيولي

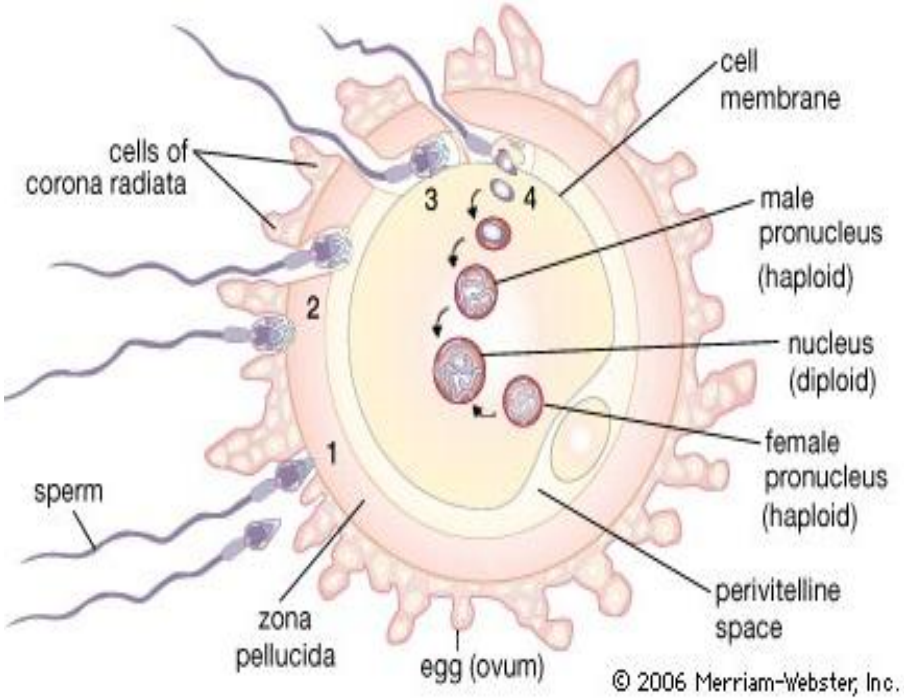
cell membrane
cells of corona radiata
3
4
male pronucleus (haploid)
2
nucleus (diploid)
female pronucleus (haploid)
1
sperm
perivitelline space
zona pellucida
egg (ovum)
© 2006 Merriam-Webster, Inc.

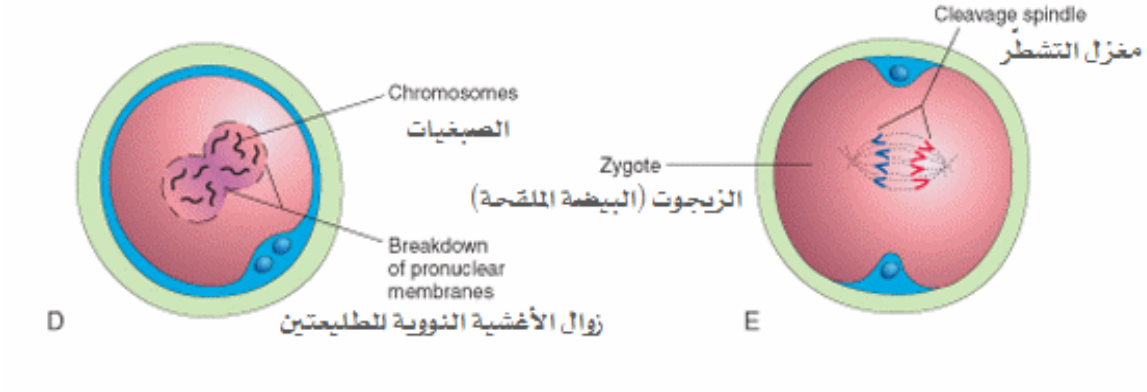
Chromosomes
الصبغيات
Breakdown of pronuclear membranes
D
زوال الأغشية النووية للطليعتين
Cleavage spindle
مغزل التشطّر
Zygote
الزيجوت (البيضة الملقحة)
E

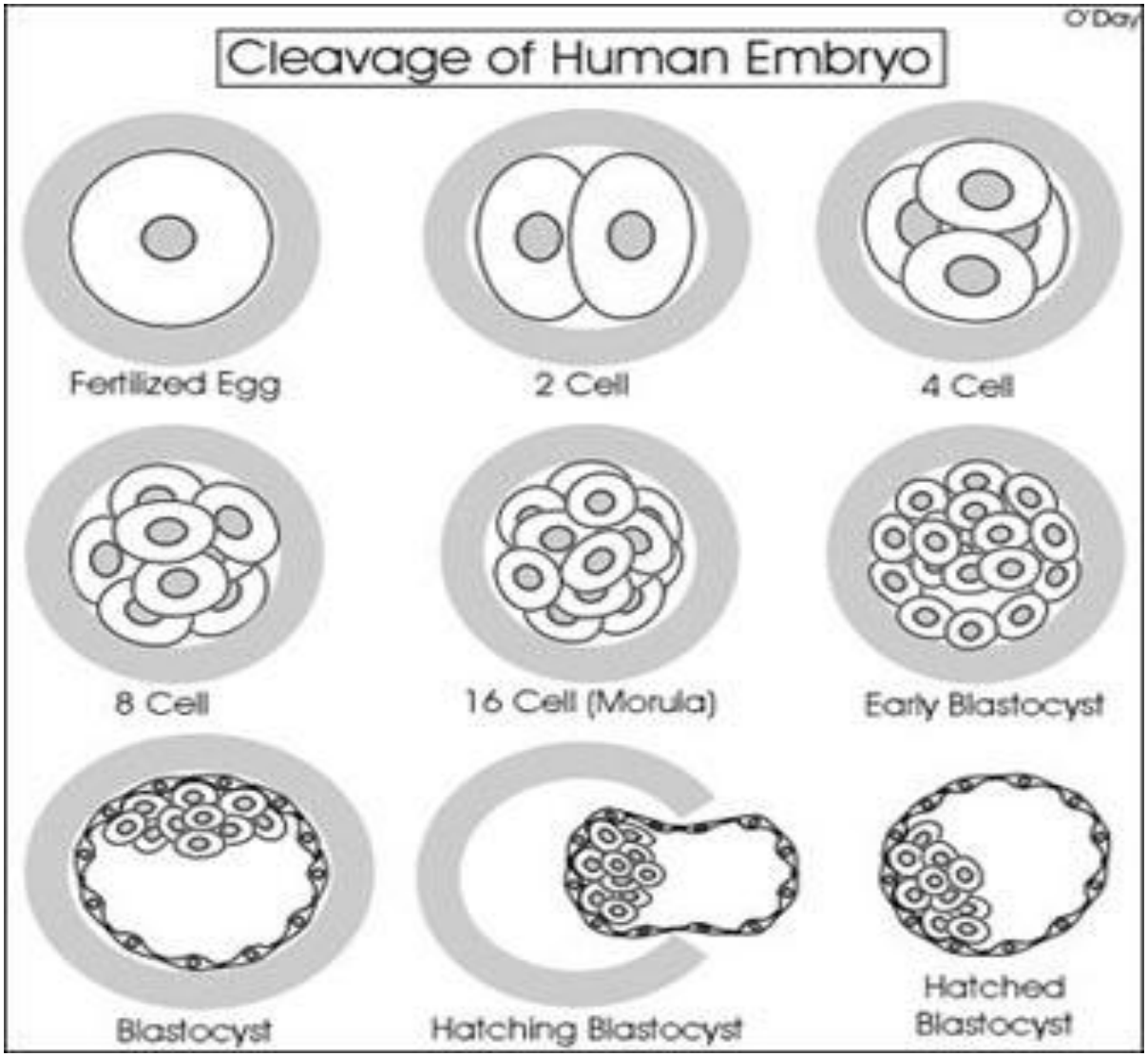
O'Day
Cleavage of Human Embryo
Fertilized Egg
2 Cell
4 Cell
8 Cell
16 Cell (Morula)
Early Blastocyst
Blastocyst
Hatching Blastocyst
Hatched Blastocyst

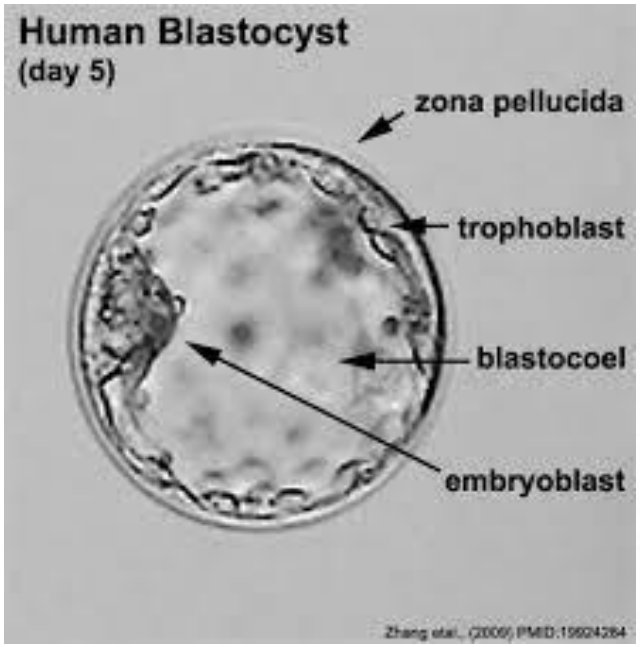
Human Blastocyst
(day 5)
zona pellucida
trophoblast
blastocoel
embryoblast
Zhang etal., (2006) PMID:19624284

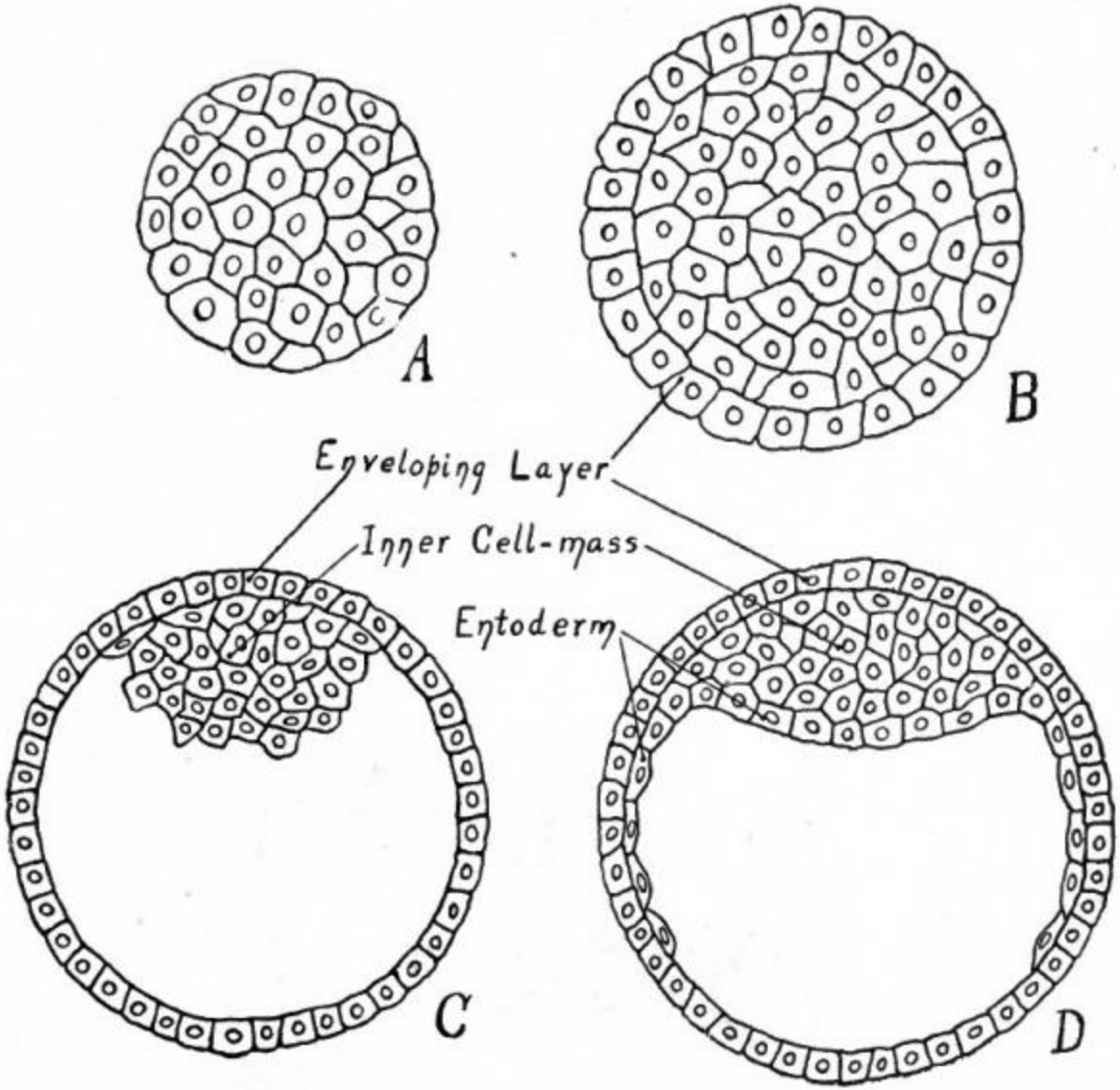
A
B
Enveloping Layer
Inner Cell-mass
Entoderm
C
D

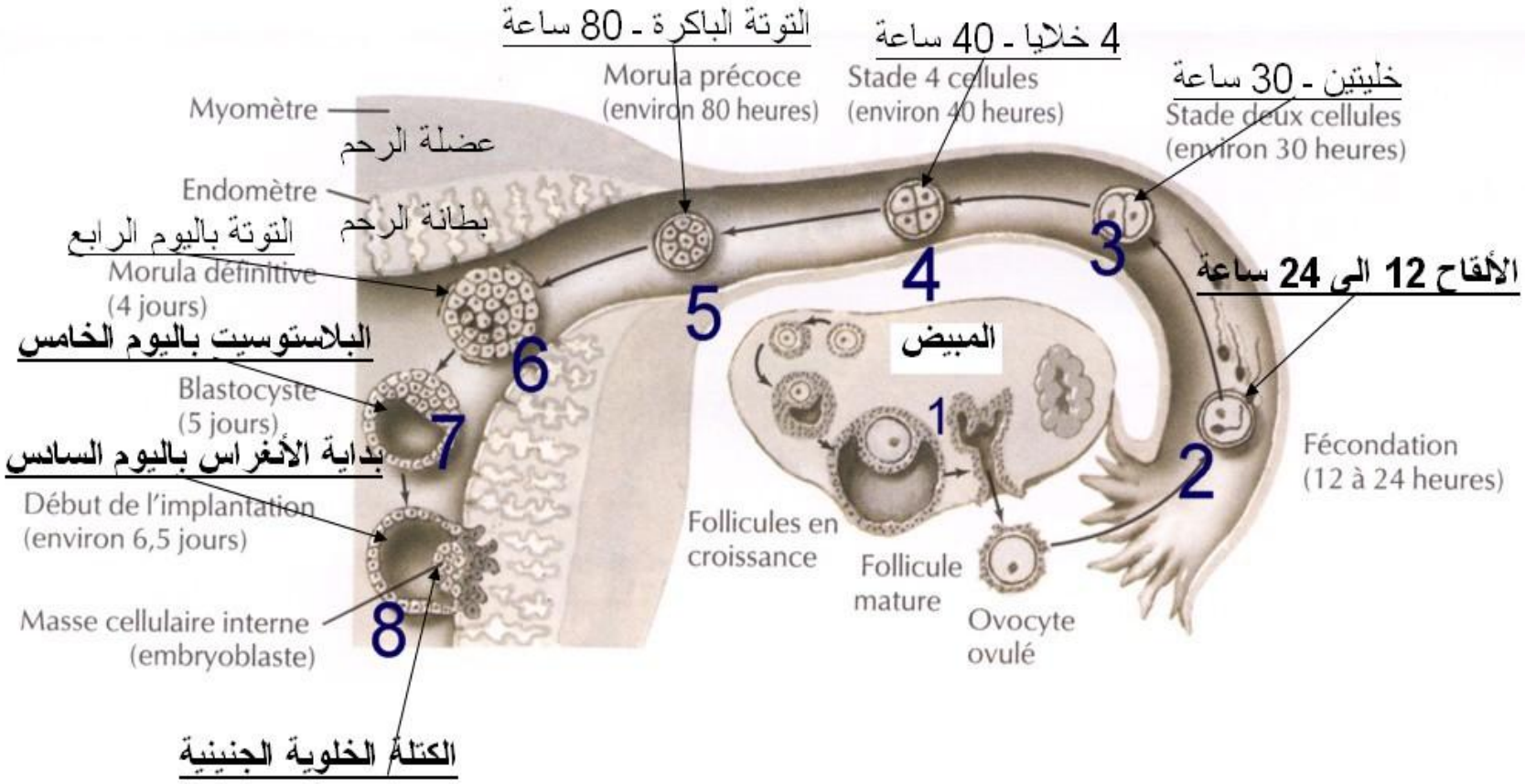
التوتة الباكرة - 80 ساعة
Morula précoce
(environ 80 heures)
4 خلايا - 40 ساعة
Stade 4 cellules
(environ 40 heures)
خليتين - 30 ساعة
Stade deux cellules
(environ 30 heures)
Myomètre
عضلة الرحم
Endomètre
بطانة الرحم
التوتة باليوم الرابع
Morula définitive
(4 jours)
الألقاح 12 الى 24 ساعة
البلاستوسيت باليوم الخامس
Blastocyste
(5 jours)
بداية الأغراس باليوم السادس
Début de l'implantation
(environ 6,5 jours)
Masse cellulaire interne
(embryoblaste)
الكتلة الخلوية الجنينية
المبيض
Follicules en
croissance
Follicule
mature
Ovocyte
ovulé
Fécondation
(12 à 24 heures)
1
2
3
4
5
6
7
8

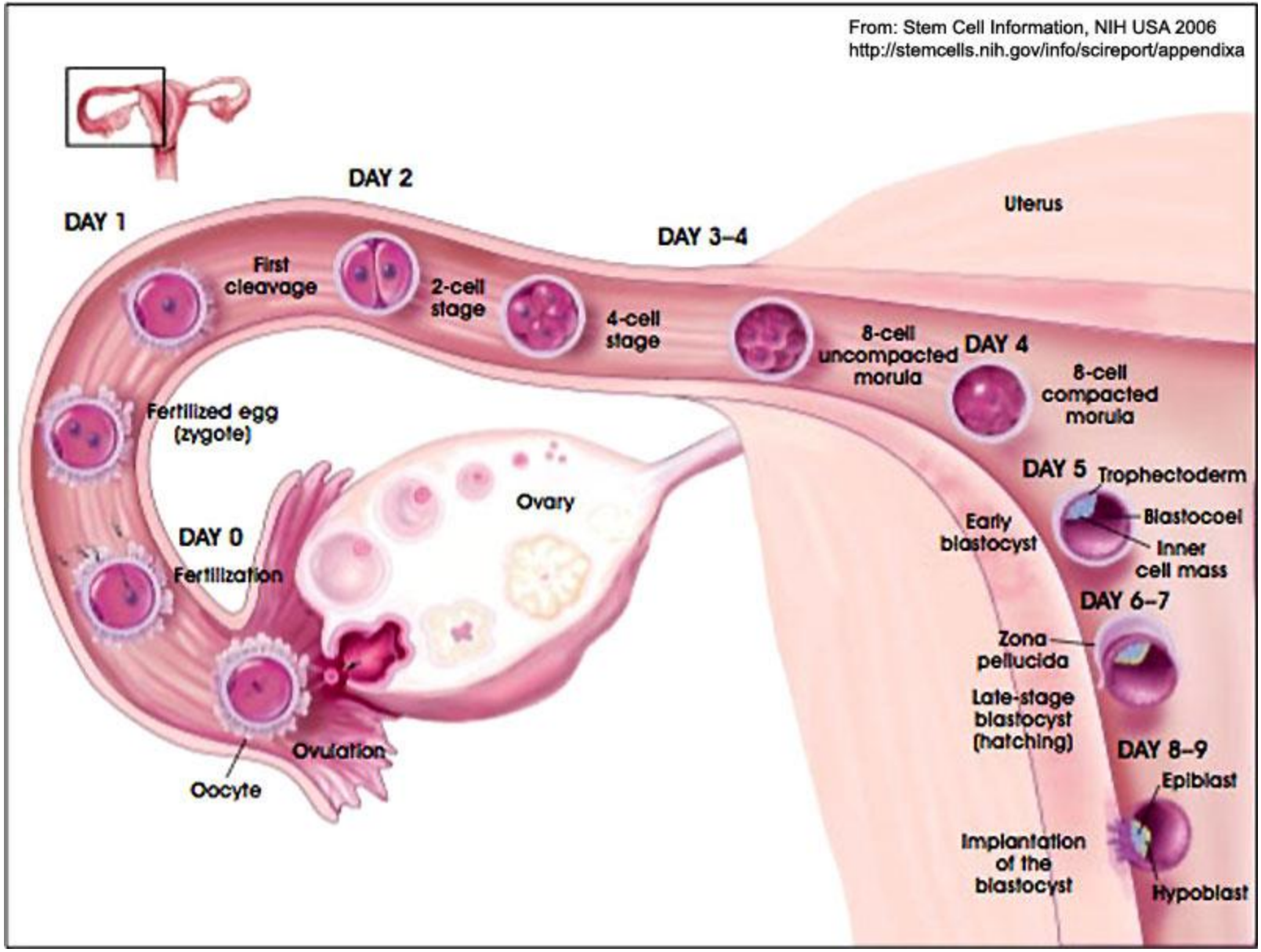
From: Stem Cell Information, NIH USA 2006
http://stemcells.nih.gov/info/scireport/appendixa
DAY 1
DAY 2
DAY 3–4
DAY 4
DAY 5
DAY 6–7
DAY 8–9
DAY 0
Uterus
First cleavage
2-cell stage
4-cell stage
8-cell uncompacted morula
8-cell compacted morula
Fertilized egg (zygote)
Ovary
Fertilization
Ovulation
Oocyte
Trophectoderm
Blastocoel
Inner cell mass
Early blastocyst
Zona pellucida
Late-stage blastocyst (hatching)
Epiblast
Hypoblast
Implantation of the blastocyst

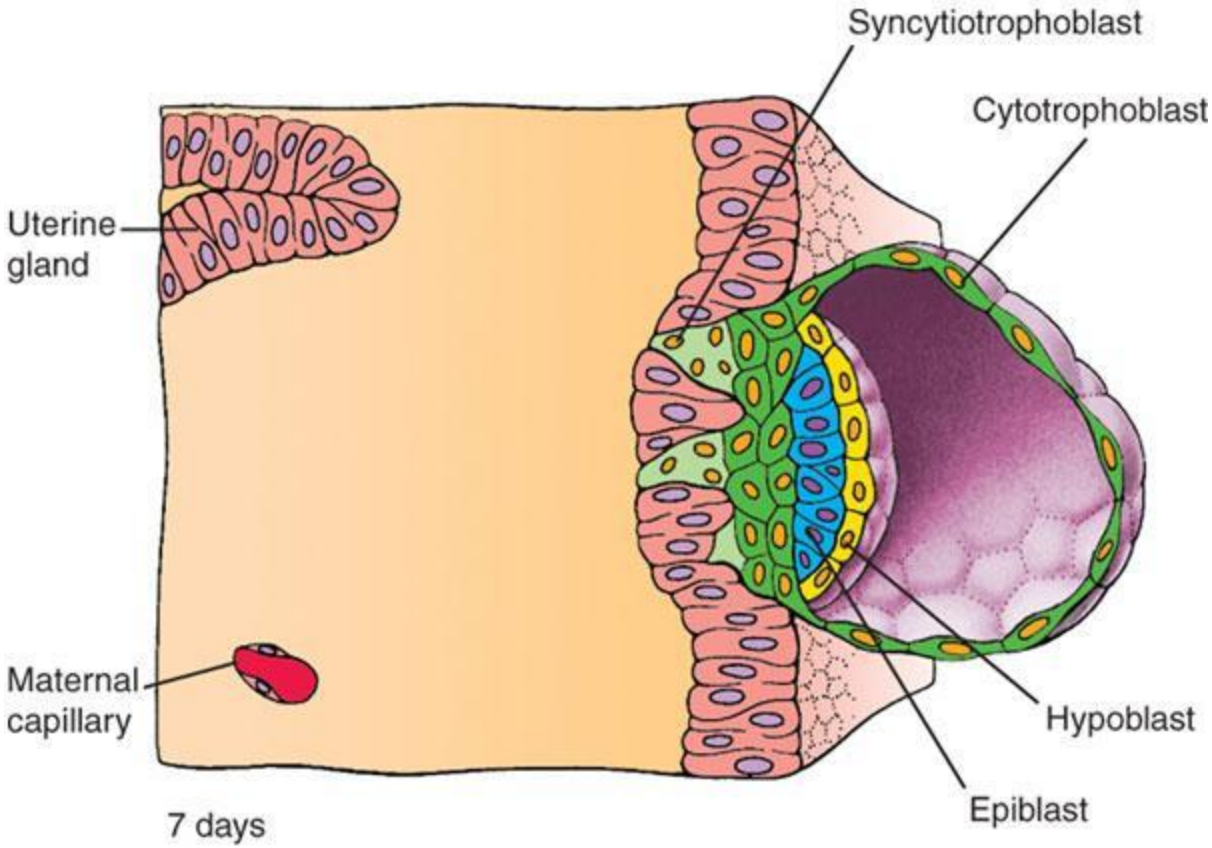
Syncytiotrophoblast
Cytotrophoblast
Uterine gland
Maternal capillary
Hypoblast
Epiblast
7 days

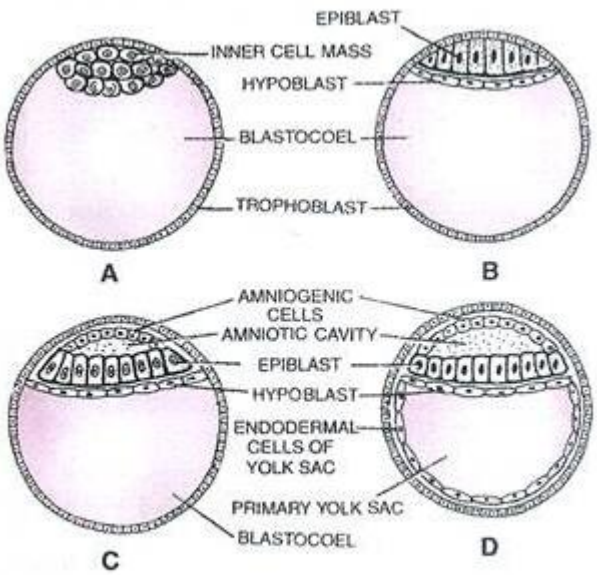

Diagrams showing formation of epiblast, hypoblast, amniotic cavity and yolk sac.

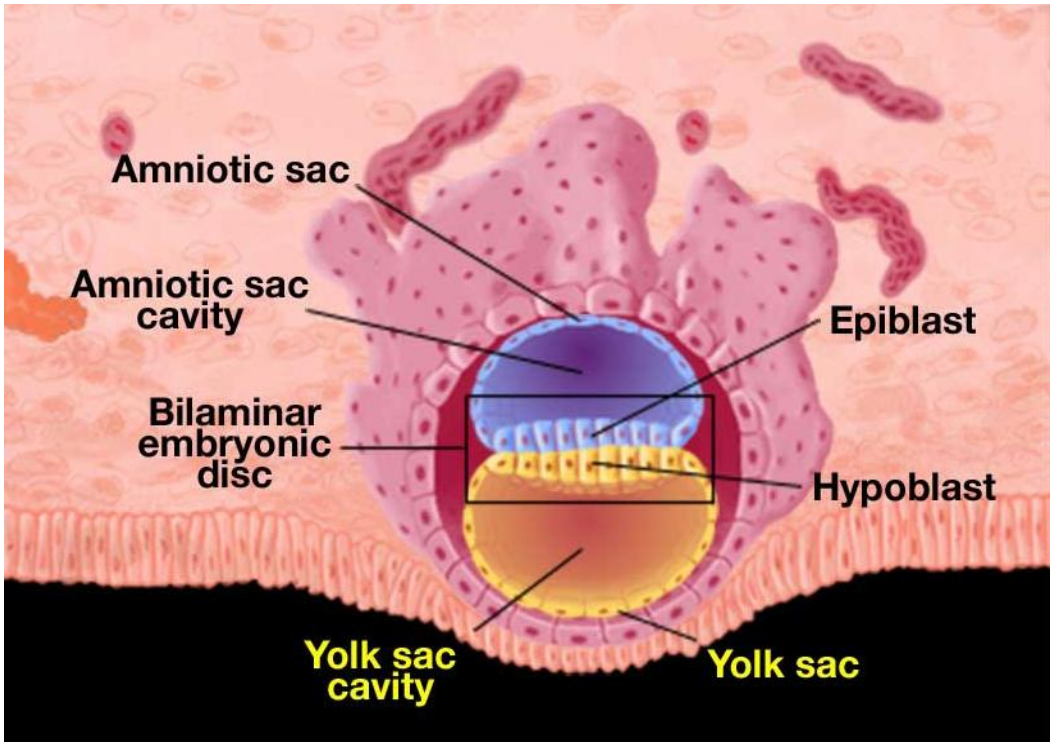

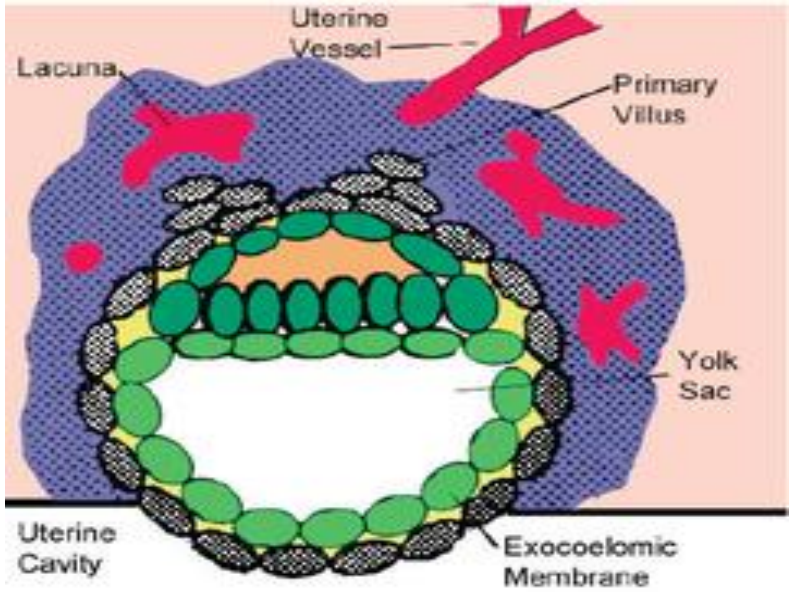
Uterine
Vessel
Lacuna
Primary
Villus
Yolk
Sac
Uterine
Cavity
Exocoelomic
Membrane

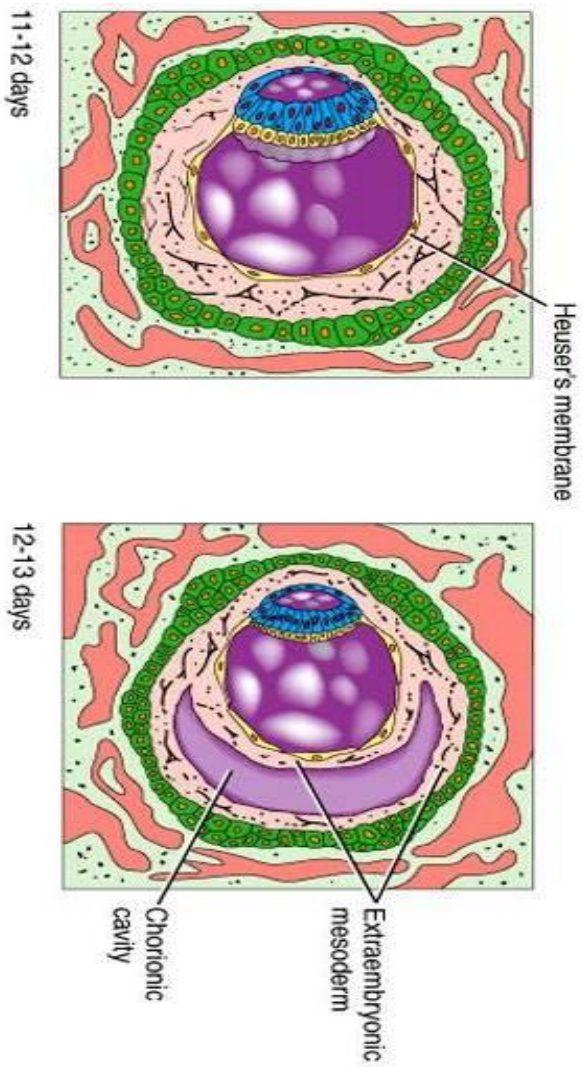
11-12 days
Heuser's membrane
12-13 days
Chorionic cavity
Extraembryonic mesoderm

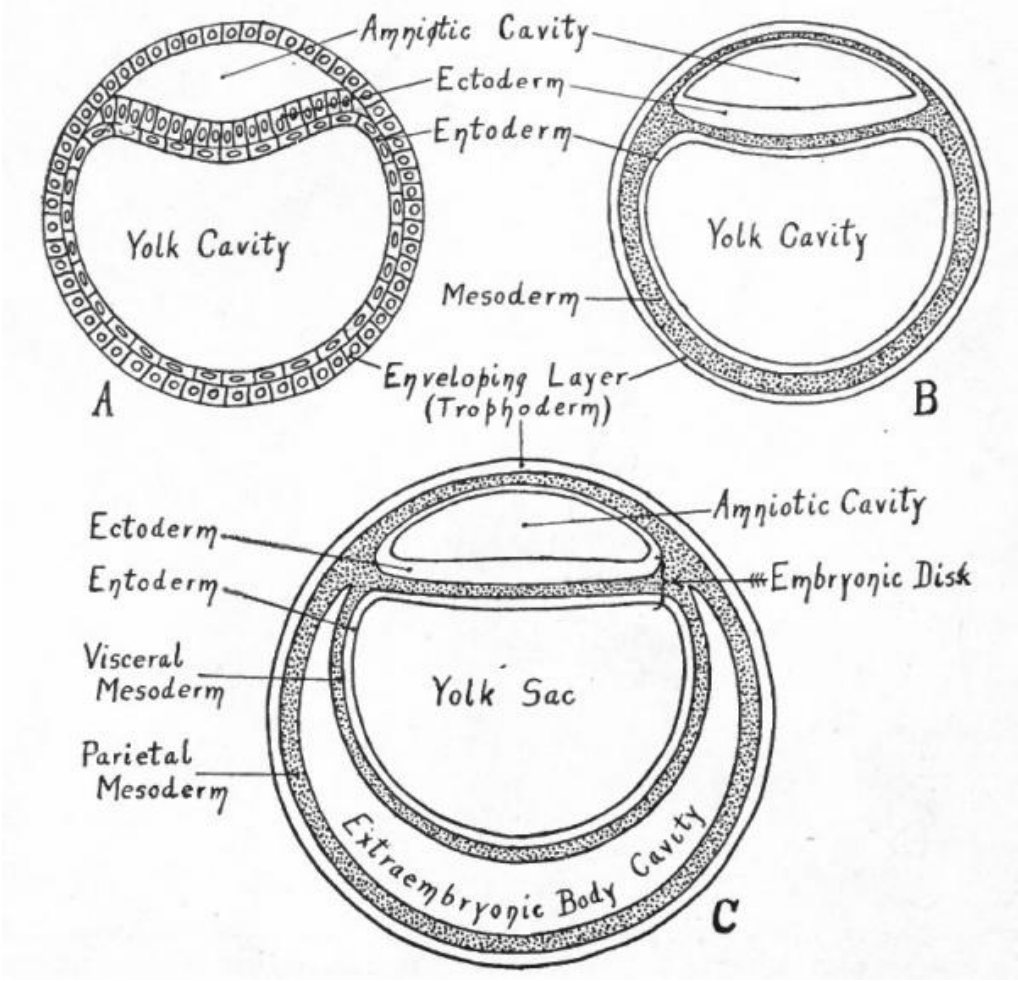
Amniotic Cavity
Ectoderm
Entoderm
Yolk Cavity
Yolk Cavity
Mesoderm
Enveloping Layer
(Trophoderm)
A
B
Amniotic Cavity
Ectoderm
Entoderm
Embryonic Disk
Visceral Mesoderm
Yolk Sac
Parietal Mesoderm
Extraembryonic Body Cavity
C

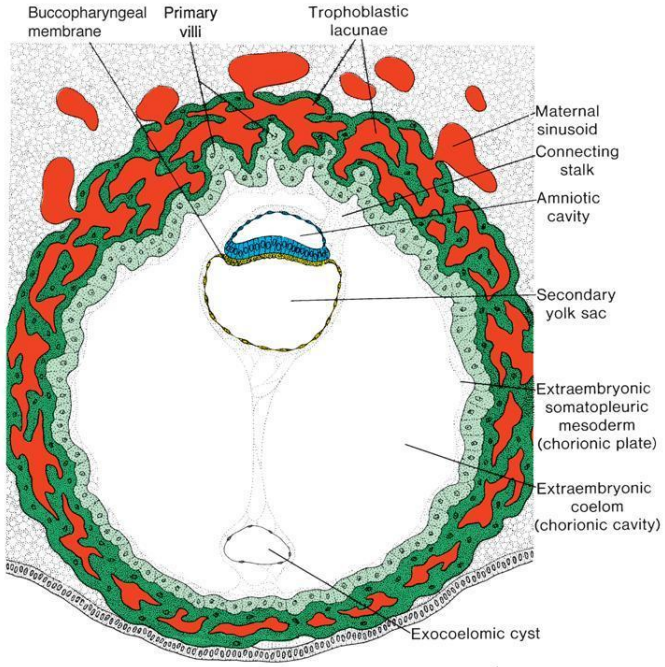
Buccopharyngeal membrane
Primary villi
Trophoblastic lacunae
Maternal sinusoid
Connecting stalk
Amniotic cavity
Secondary yolk sac
Extraembryonic somatopleuric mesoderm (chorionic plate)
Extraembryonic coelom (chorionic cavity)
Exocoelomic cyst

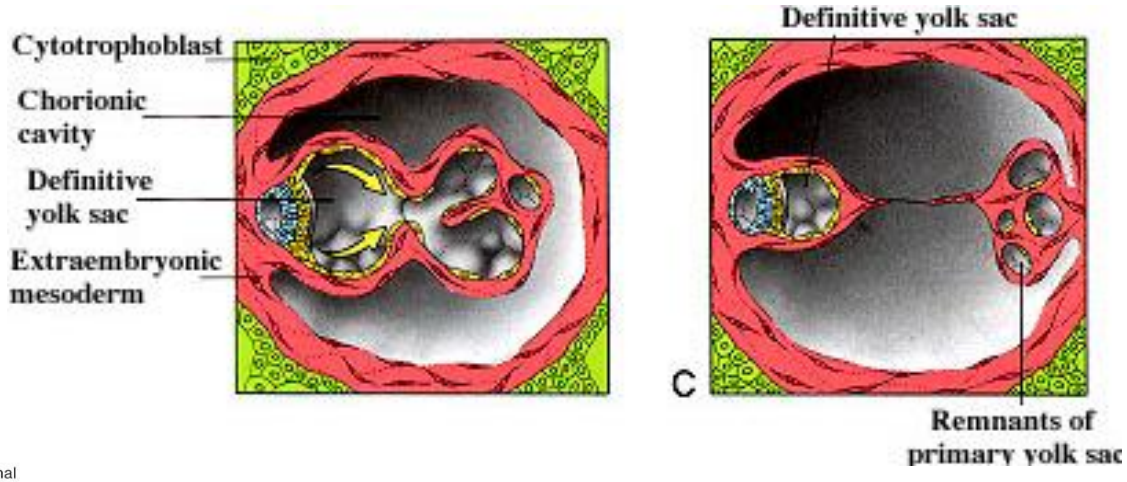
Cytotrophoblast
Chorionic cavity
Definitive yolk sac
Extraembryonic mesoderm
Definitive yolk sac
C
Remnants of primary yolk sac

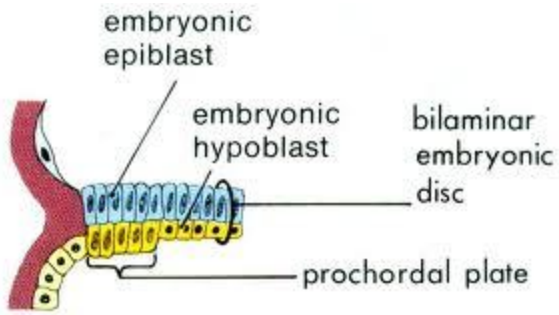
embryonic
epiblast
embryonic
hypoblast
bilaminar
embryonic
disc
prochordal plate

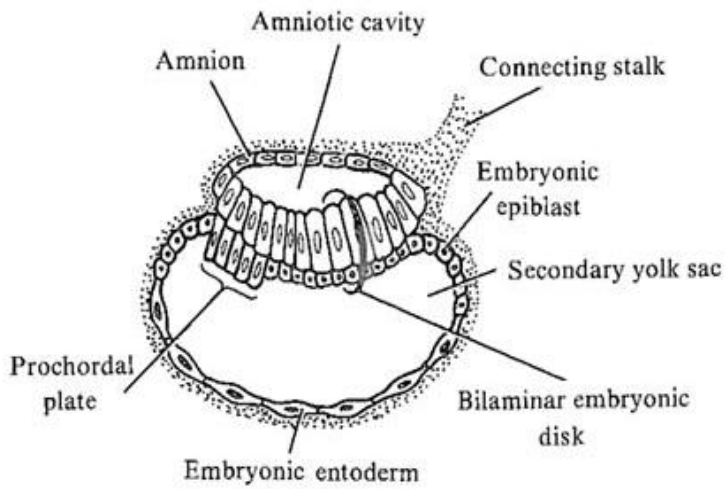
Amniotic cavity
Amnion
Connecting stalk
Embryonic
epiblast
Secondary yolk sac
Prochordal
plate
Bilaminar embryonic
disk
Embryonic entoderm

DAYS 13-14

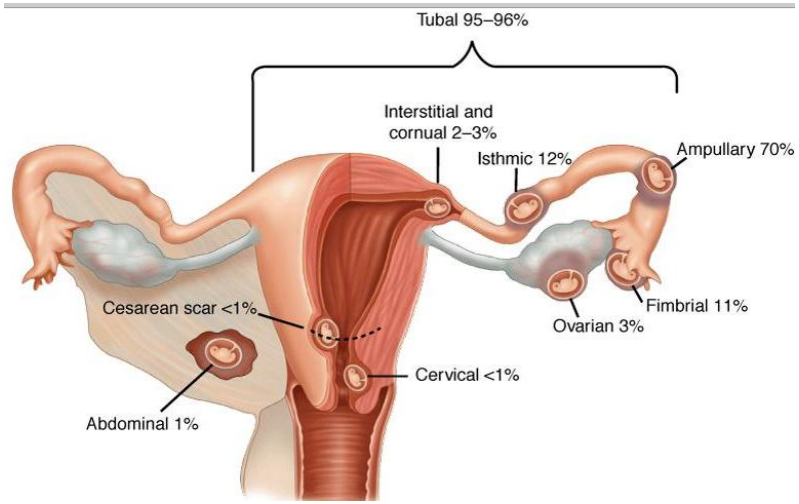
Tubal 95–96%
Interstitial and cornual 2–3%
Isthmic 12%
Ampullary 70%
Cesarean scar <1%
Fimbrial 11%
Ovarian 3%
Cervical <1%
Abdominal 1%